


# CHIRURGIE THYROIDIENNE

Dr G. POTARD  
Chirurgien ORL - CHU BREST

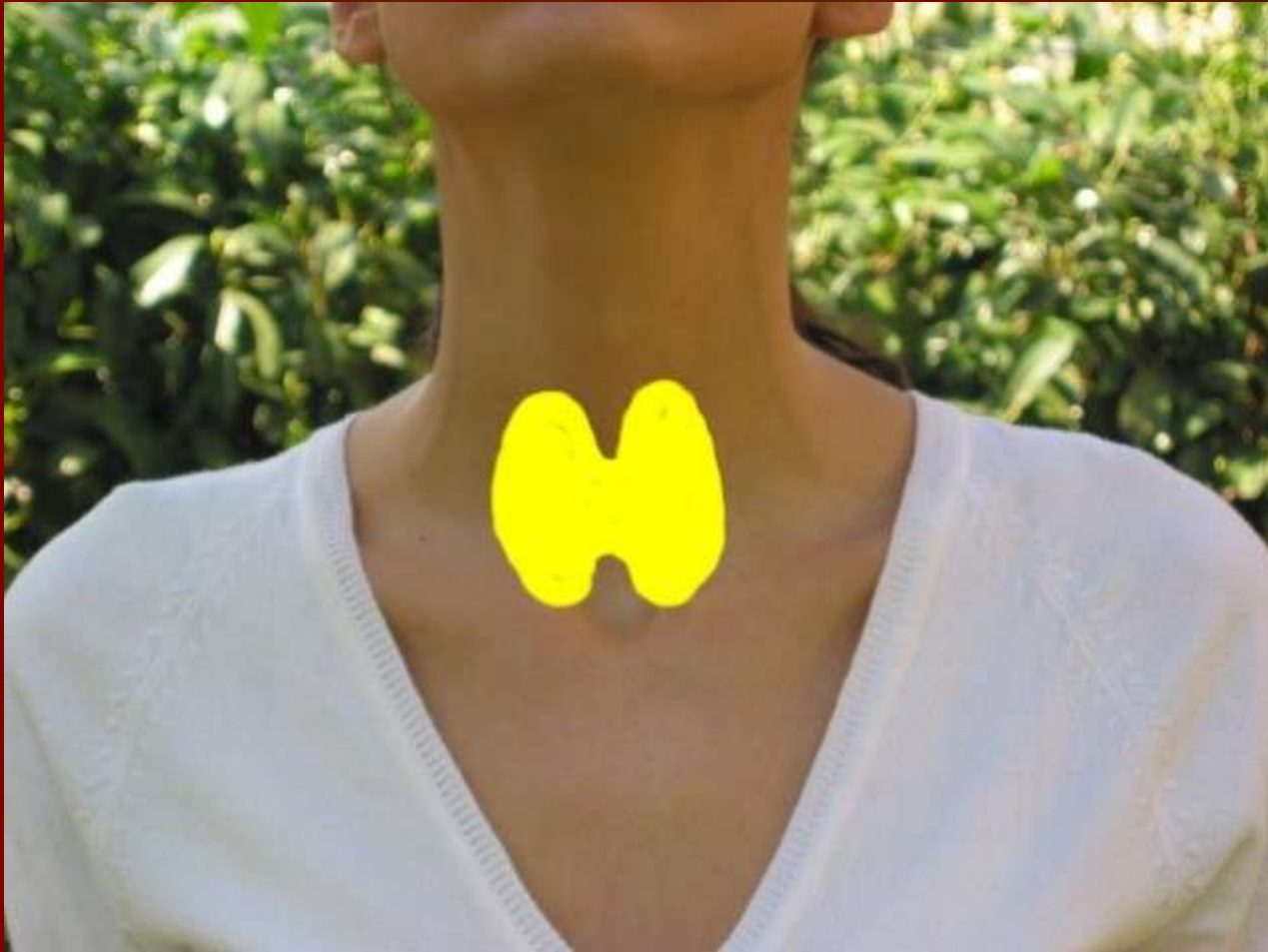
# CHIRURGIE THYROIDIENNE



# CHIRURGIE THYROIDIENNE

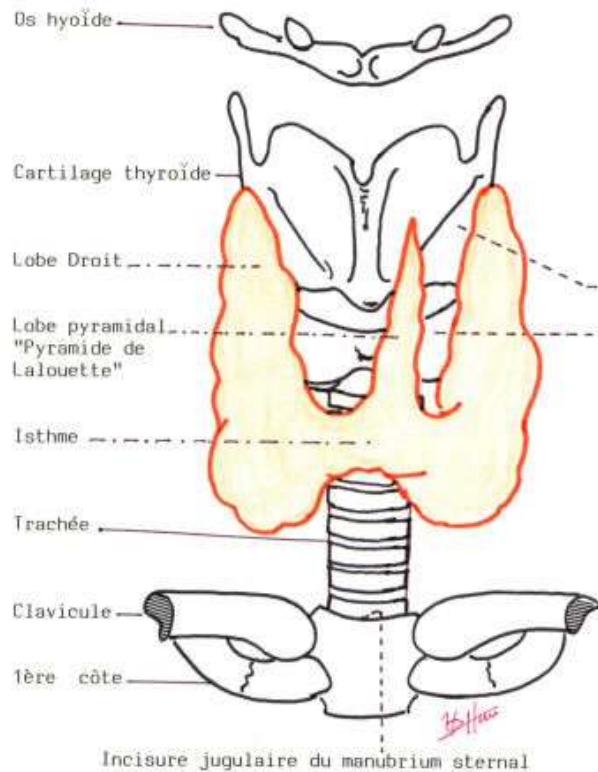
- Forme de papillon ( 2 lobes , 1 isthme ), capsule
- 25 grammes , molle, couleur brune
- 4,5 cm \* 2 cm \* 1 cm
- Coincée entre les muscles du cou et trachée
- Entourée de nombreux vaisseaux
- Nerfs récurrents , glandes parathyroïdes (4)

# CHIRURGIE THYROÏDE

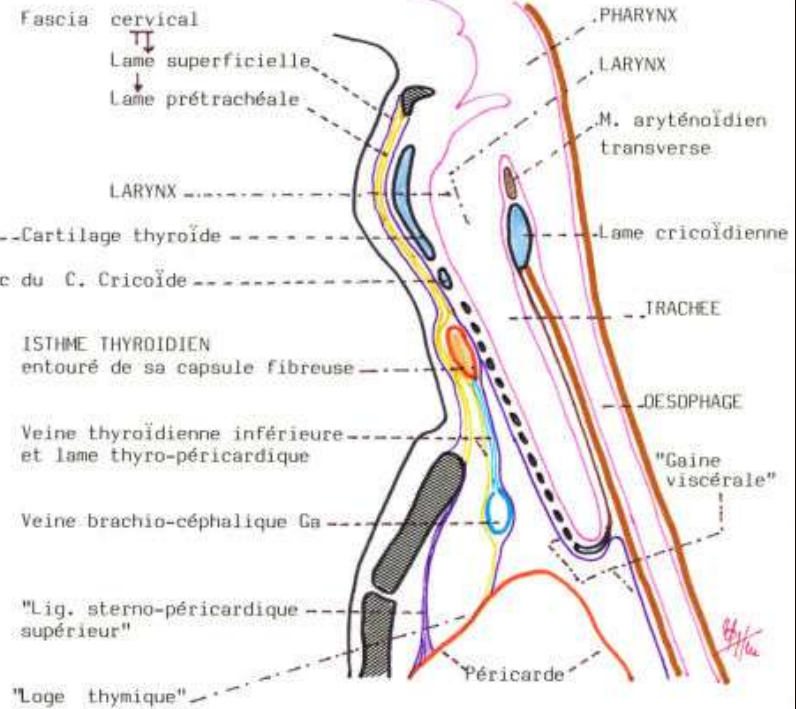


# CHIRURGIE THYROÏDE

GLANDE THYROÏDE . VUE ANTERIEURE



COUPE SAGITTALE PARAMÉDIANE



# CHIRURGIE THYROIDIENNE

- Enlève la moitié ou toute la thyroïde
- Fréquente
- Femmes ++
- Multidisciplinaire : Médecin traitant, endocrinologue , chirurgien, anatomopathologiste, médecin nucléaire

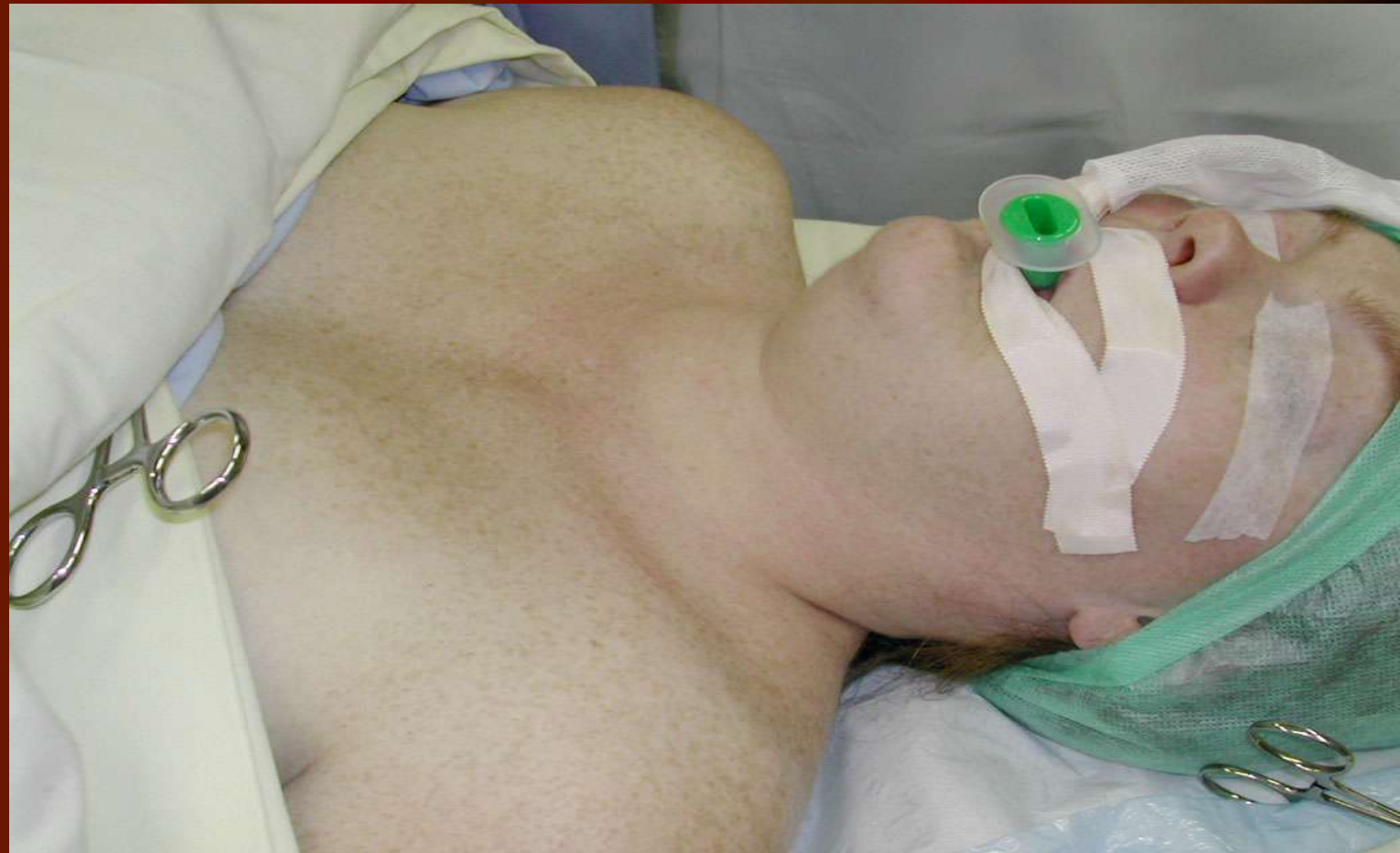# CHIRURGIE THYROIDIENNE

- Nodules (vol, crainte du cancer)
- Hyperthyroïdie non contrôlée médicalement
- Thyroïde trop volumineuse, plongeante ou gênante

# CHIRURGIE THYROIDIENNE

- INFORMATION DU PATIENT
- Risques de non intervention et de l'intervention
- Aucun acte chirurgical n'est banal
- Communs : Infection, Hématome, Cicatrice
- Spécifiques : Nerfs de la voix ou récurrents , les petites glandes parathyroïdes (4) , hormones thyroïdiennes

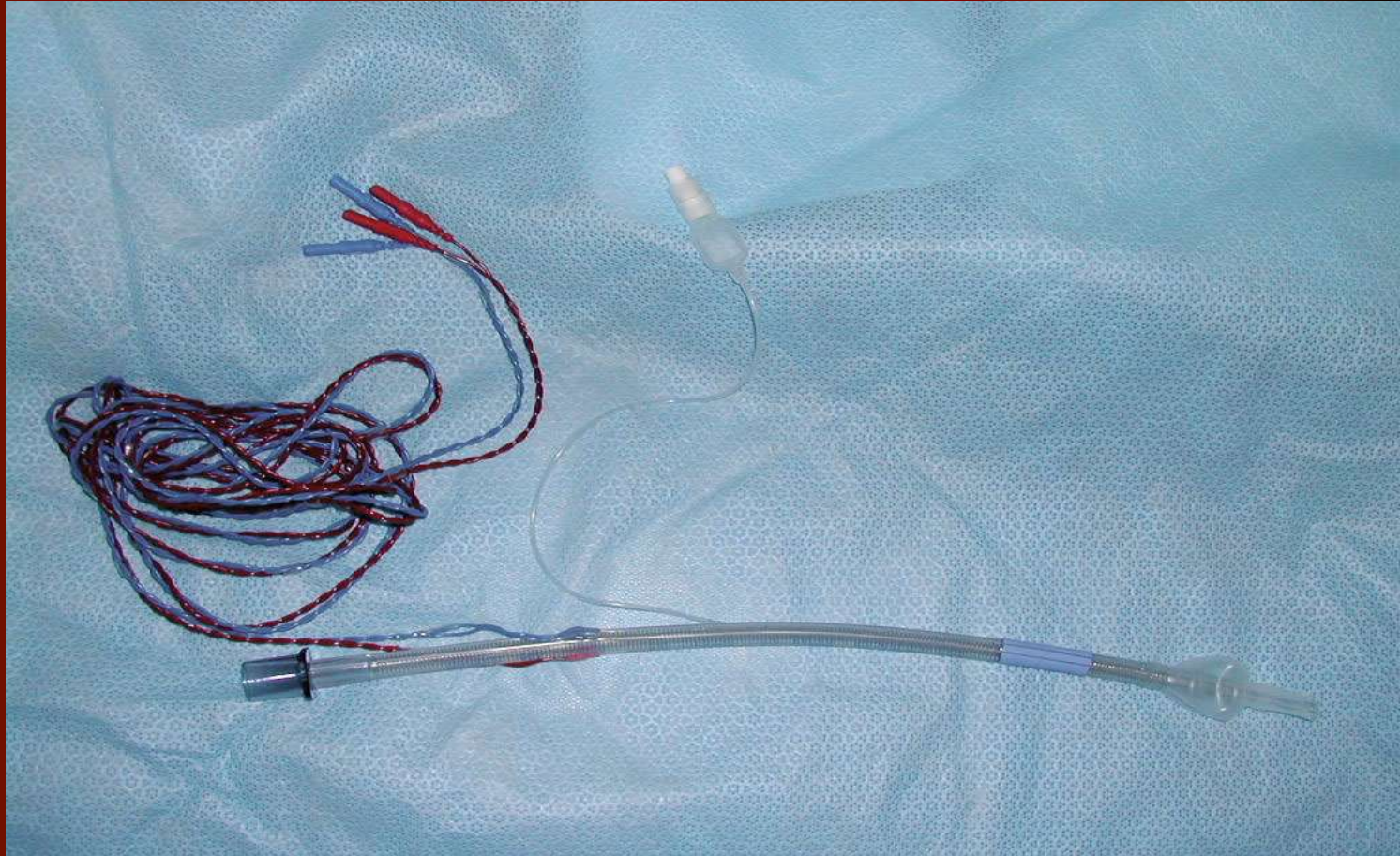
# CHIRURGIE THYROIDIENNE



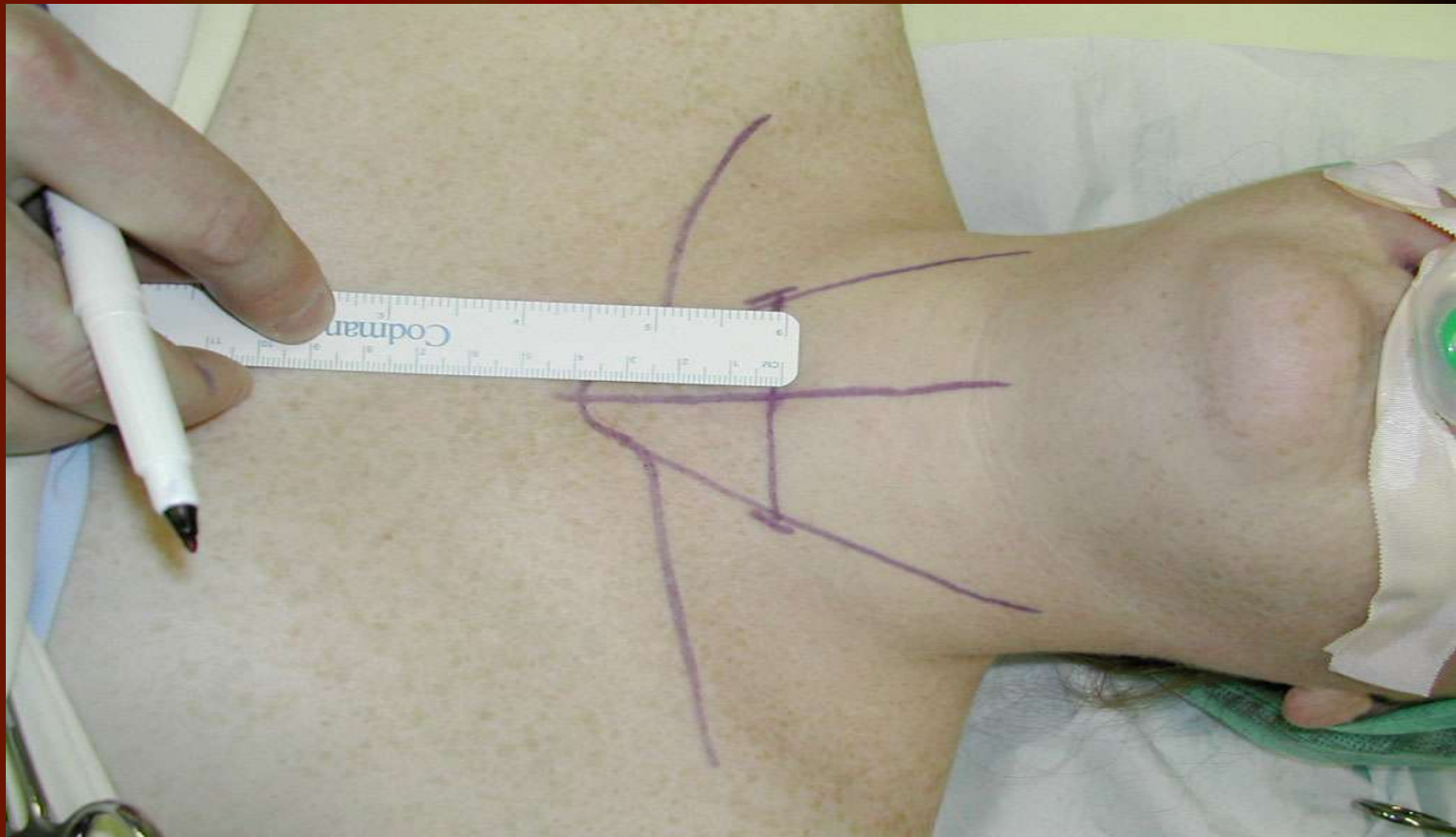
# CHIRURGIE THYROIDIENNE



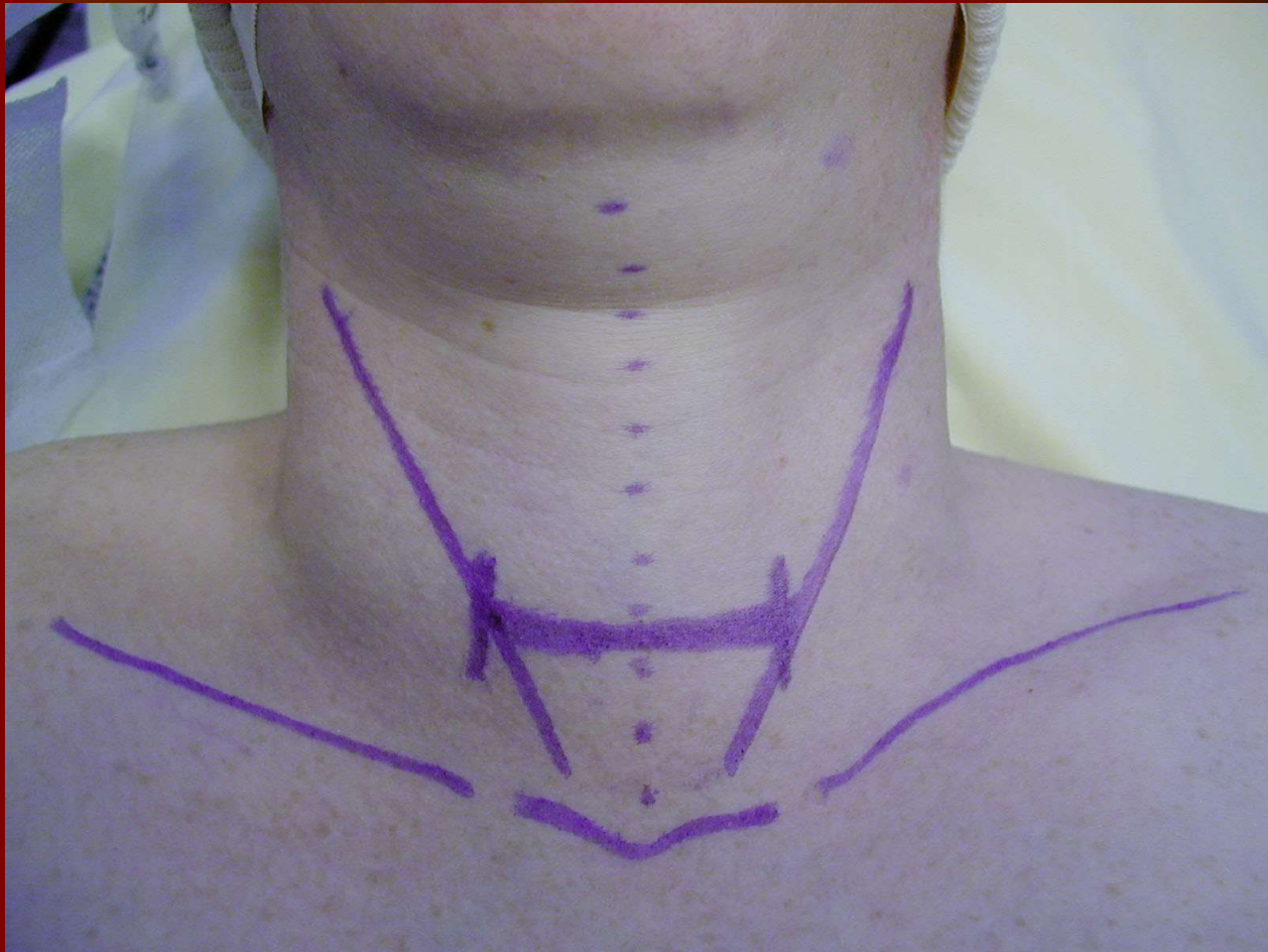
# CHIRURGIE THYROIDIENNE



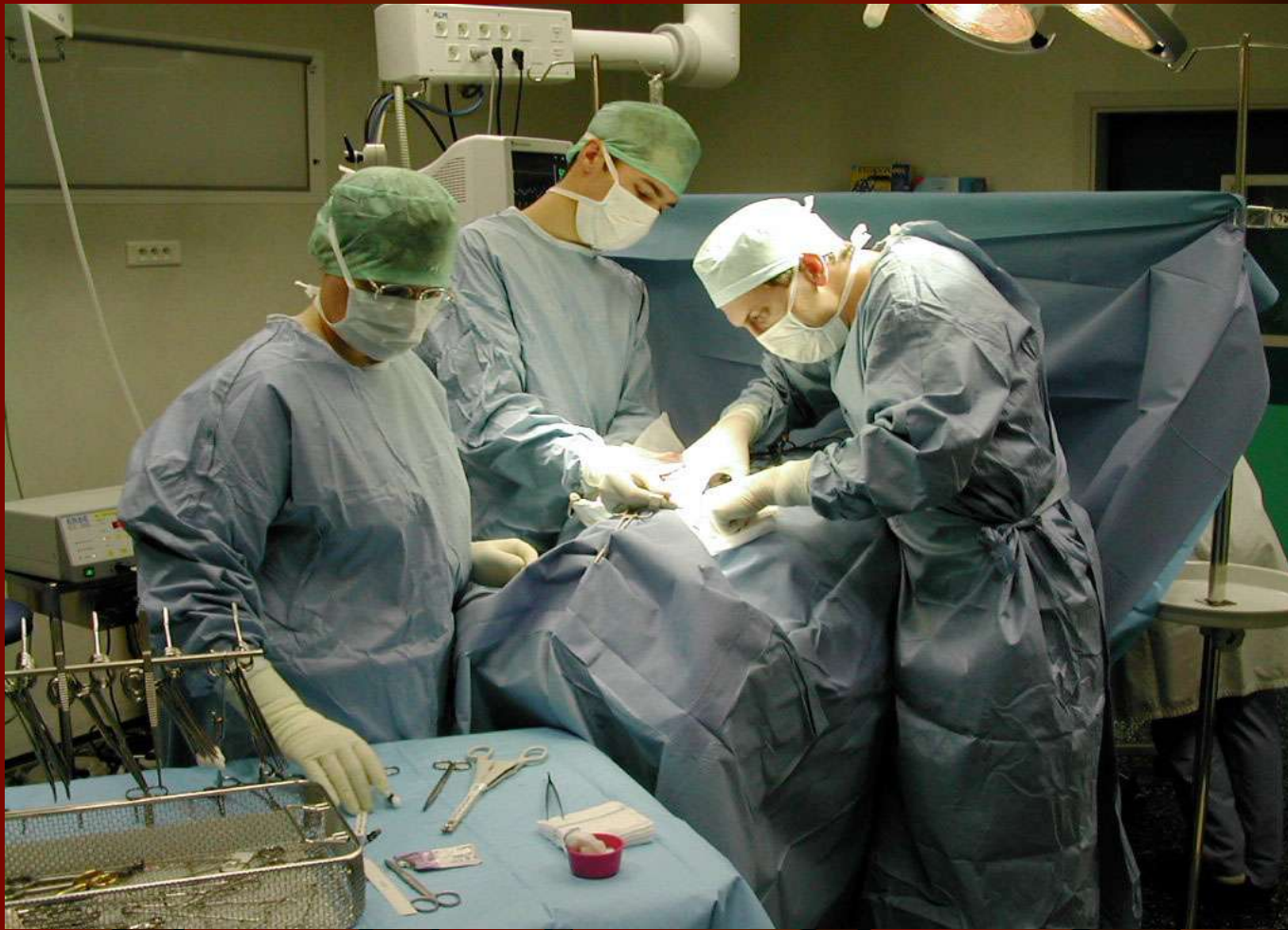# CHIRURGIE THYROIDIENNE



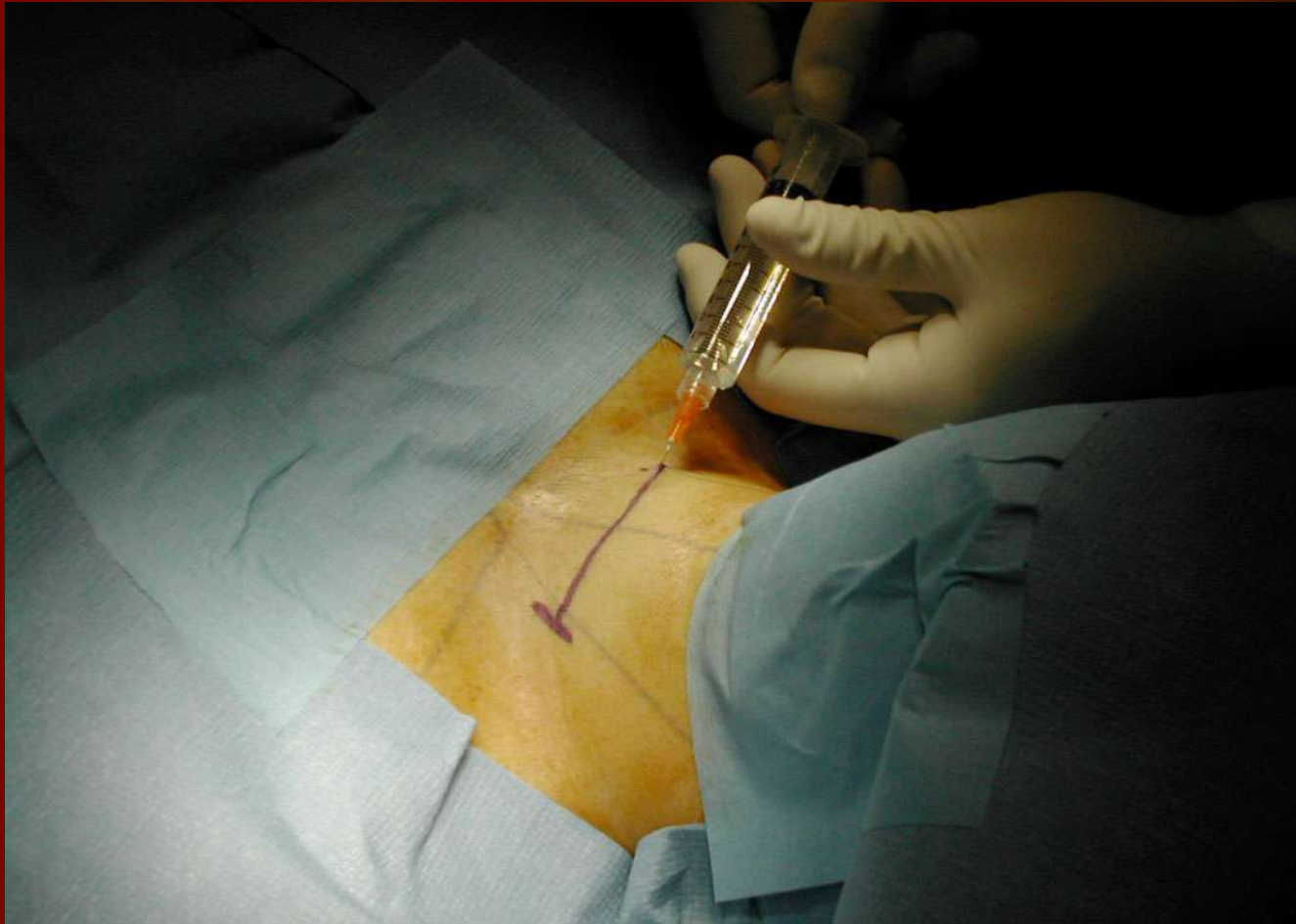# CHIRURGIE THYROIDIENNE



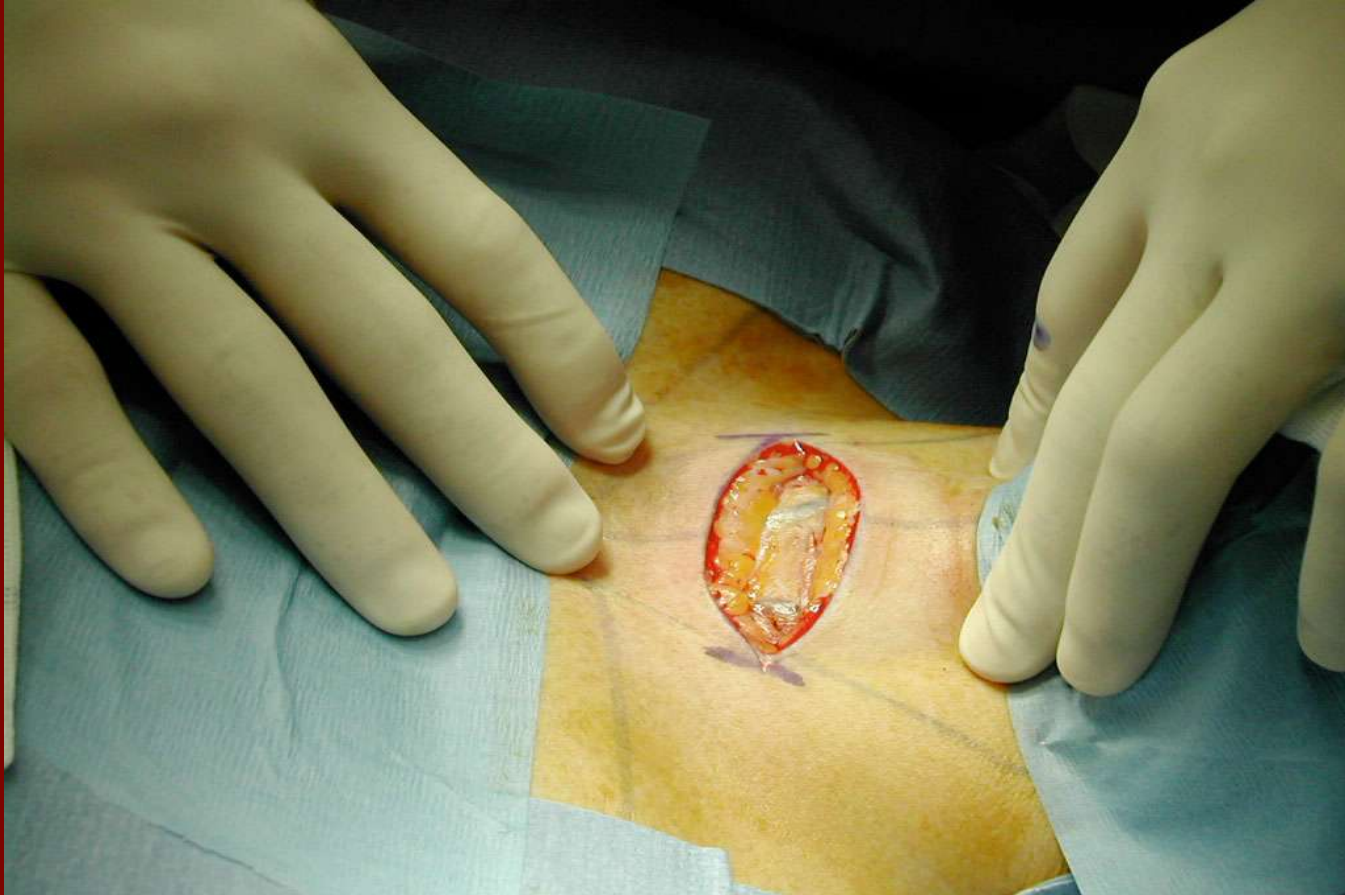
# CHIRURGIE THYROIDIENNE



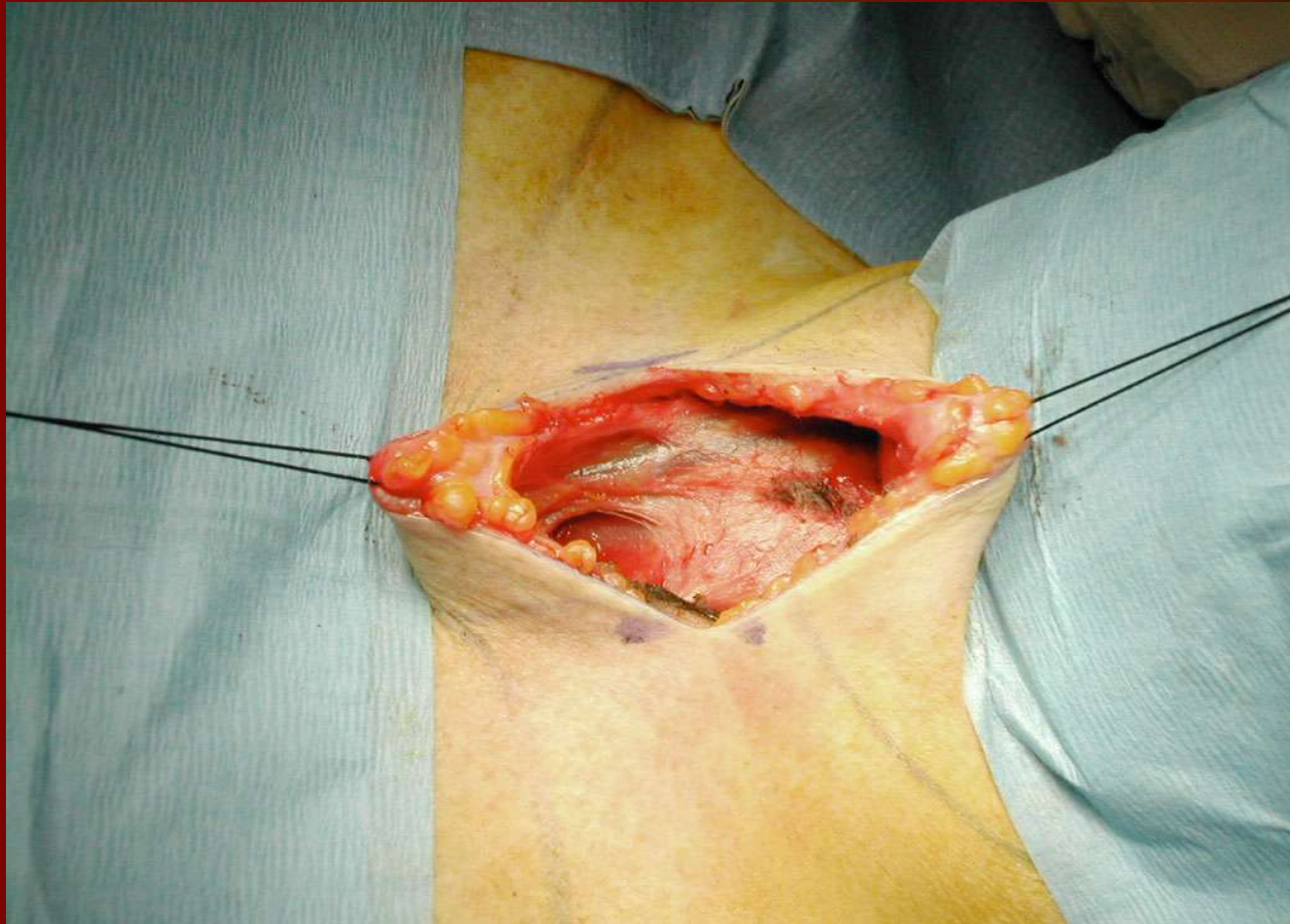
# CHIRURGIE THYROIDIENNE



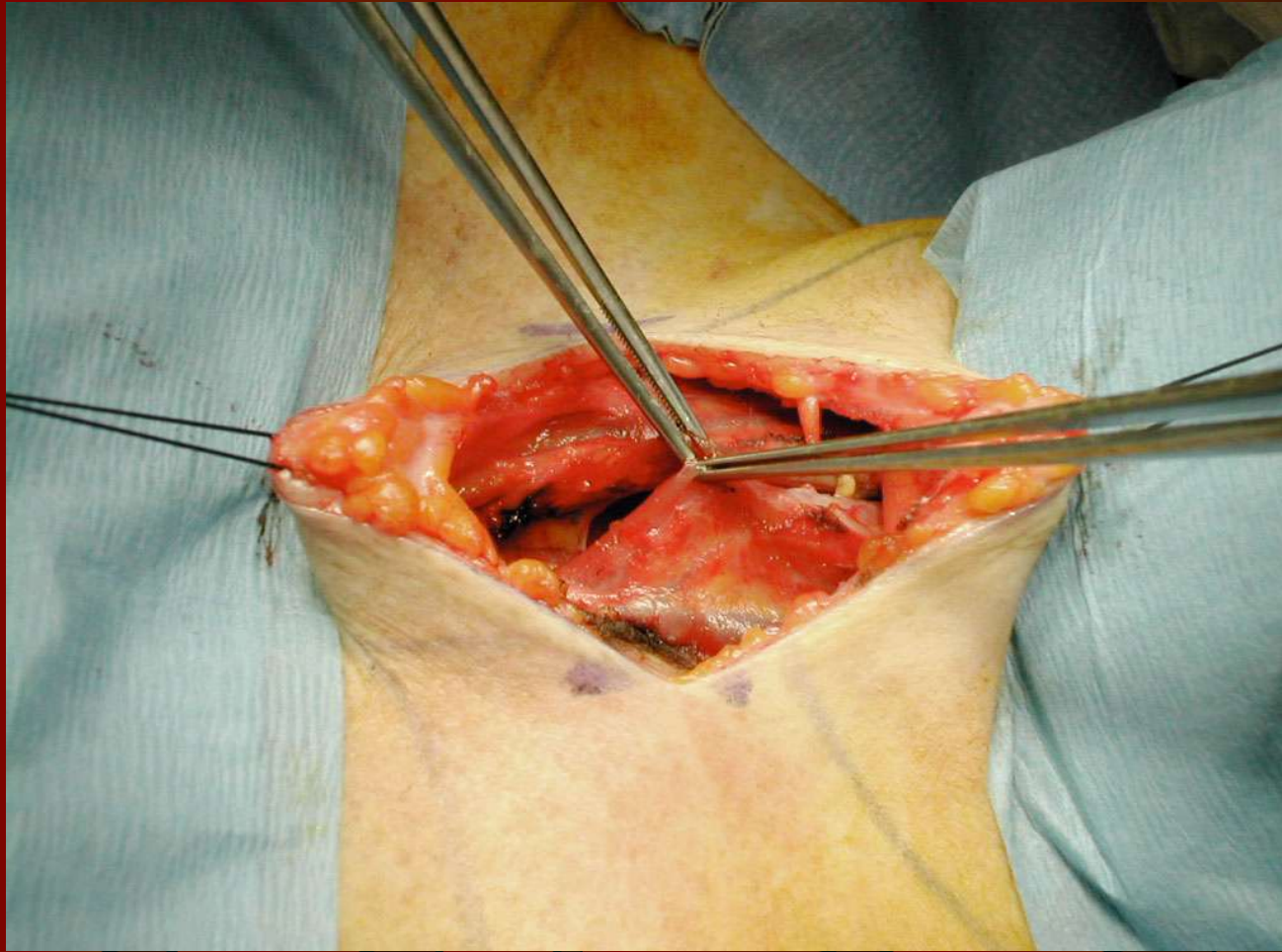
# CHIRURGIE THYROIDIENNE



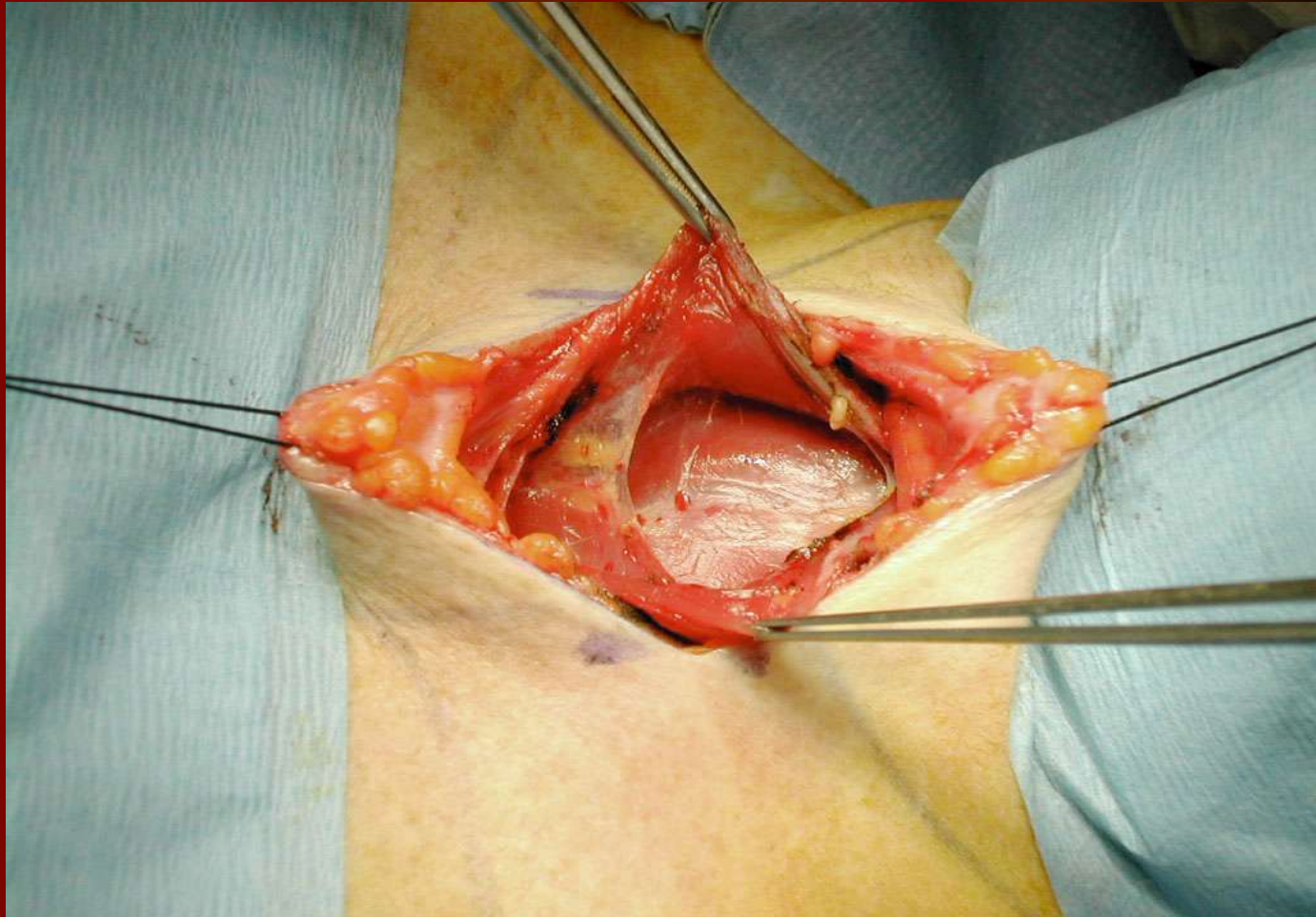
# CHIRURGIE THYROIDIENNE



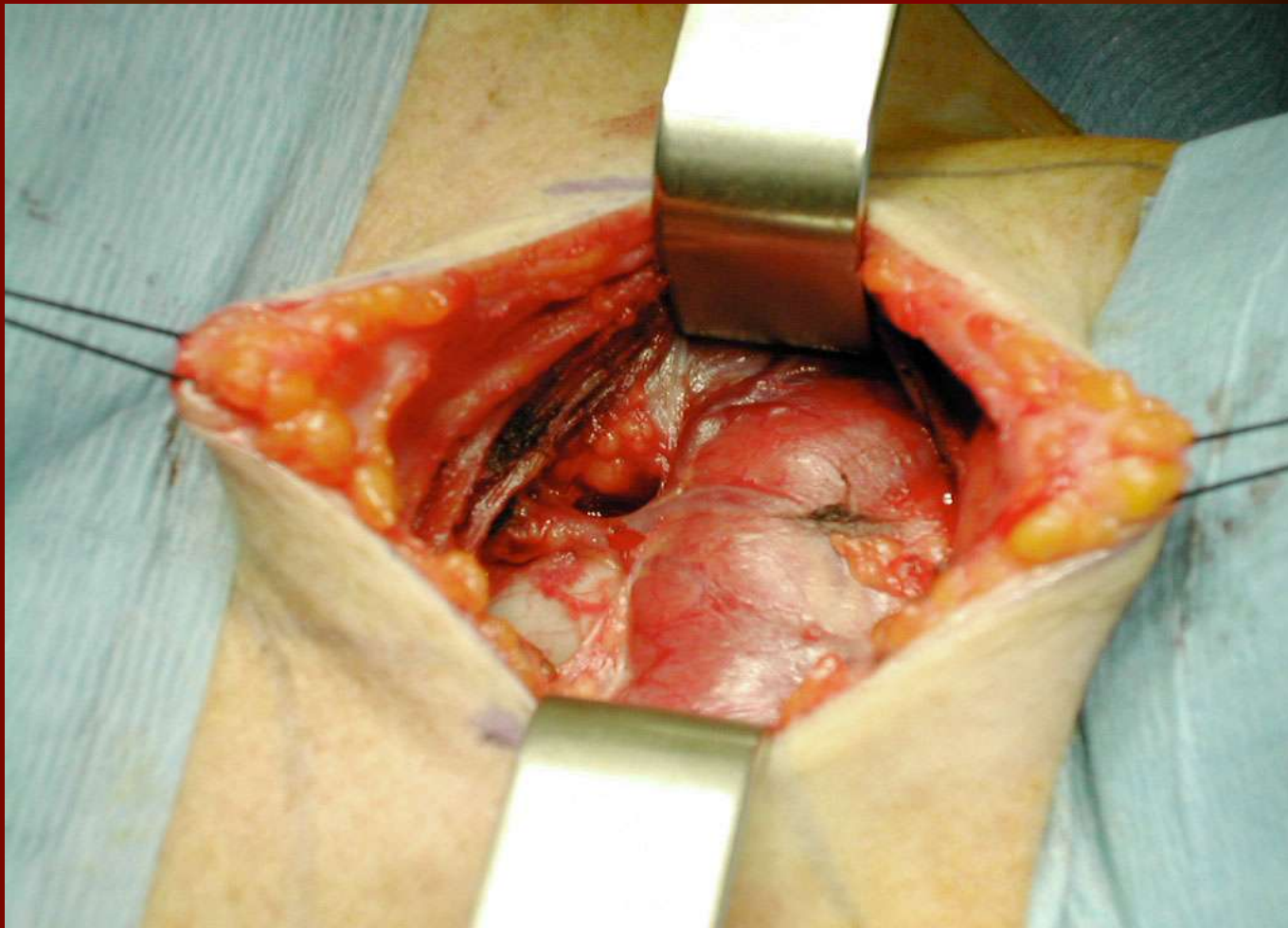
# CHIRURGIE THYROIDIENNE



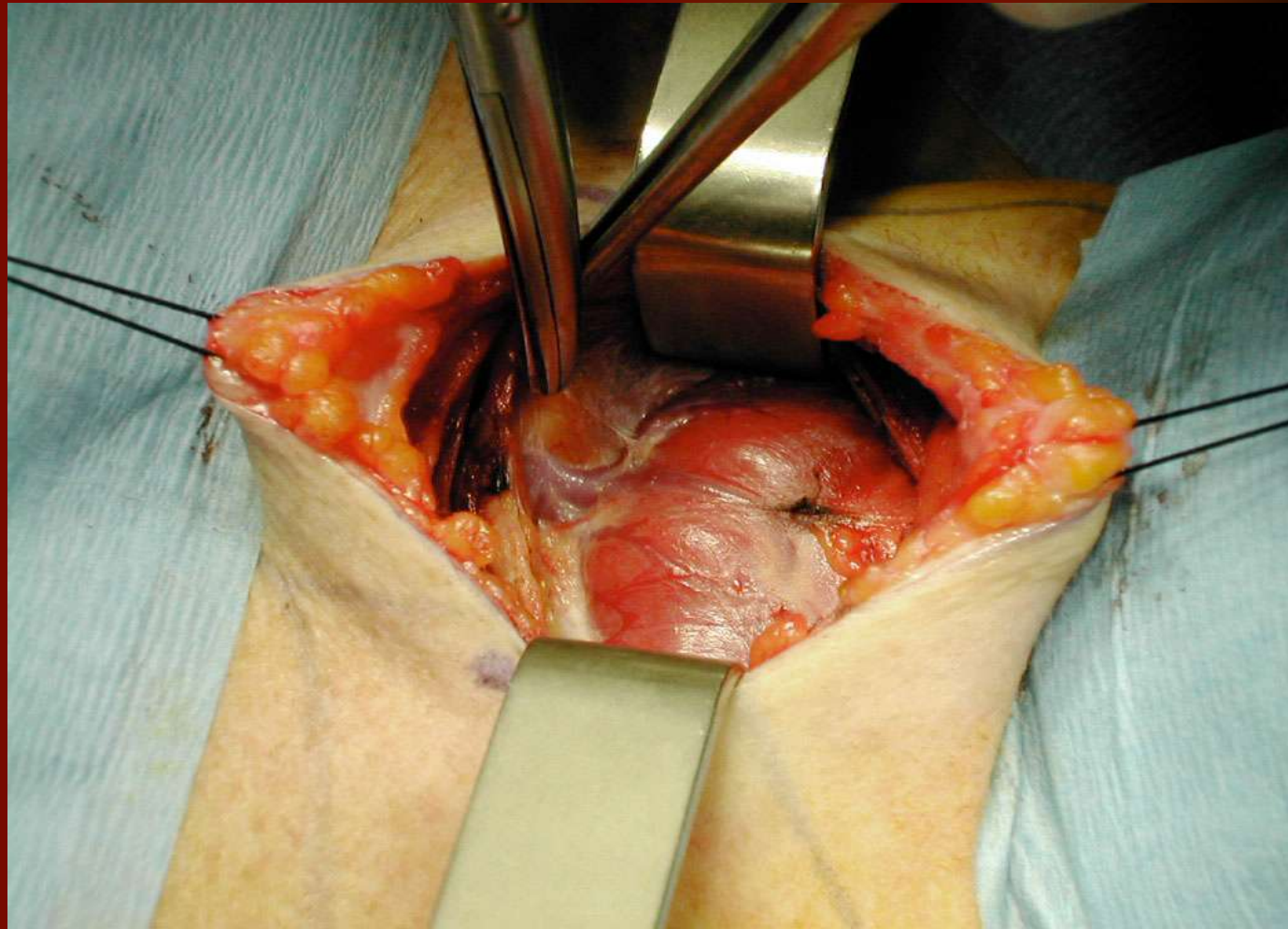
# CHIRURGIE THYROIDIENNE



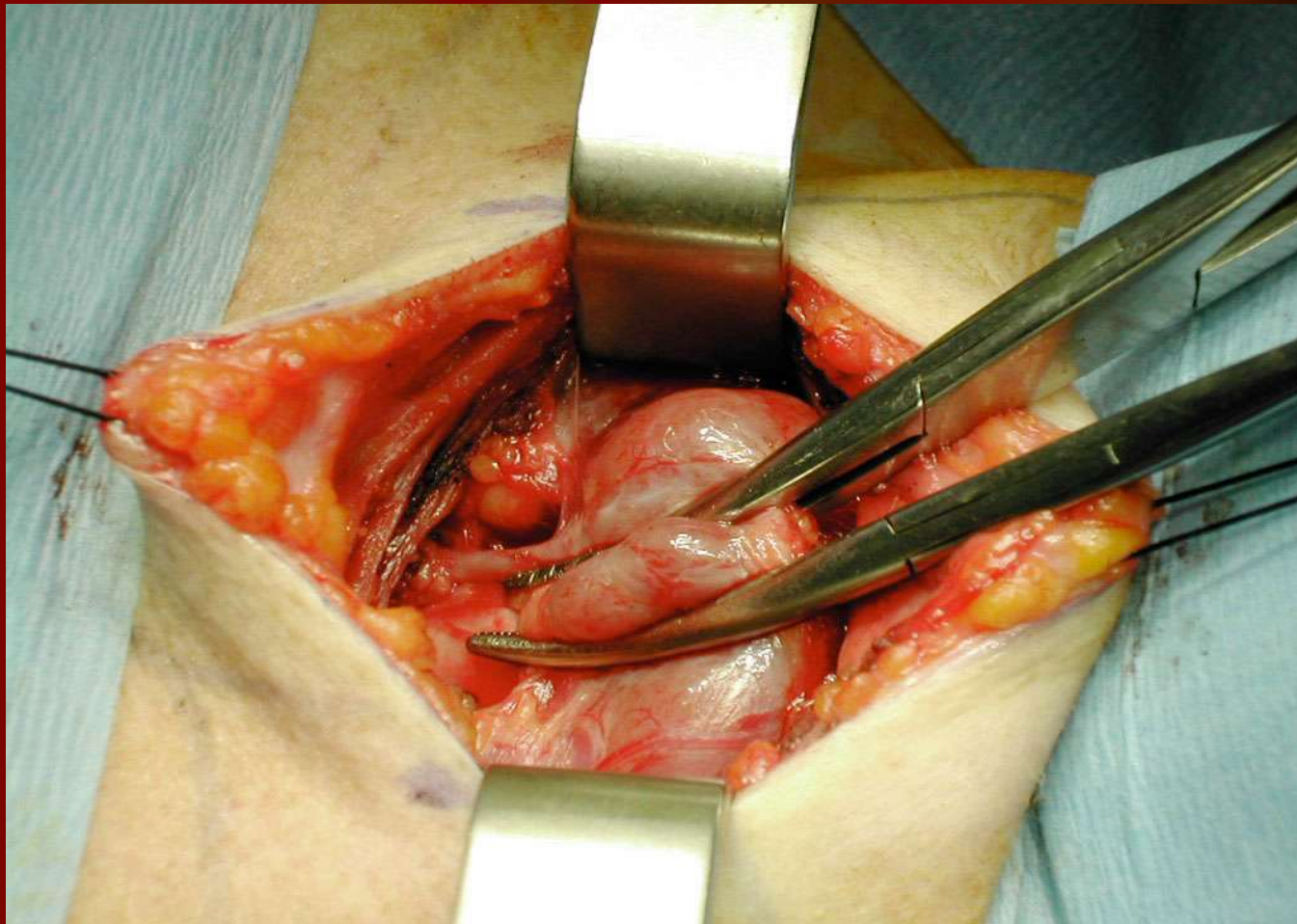
# CHIRURGIE THYROIDIENNE



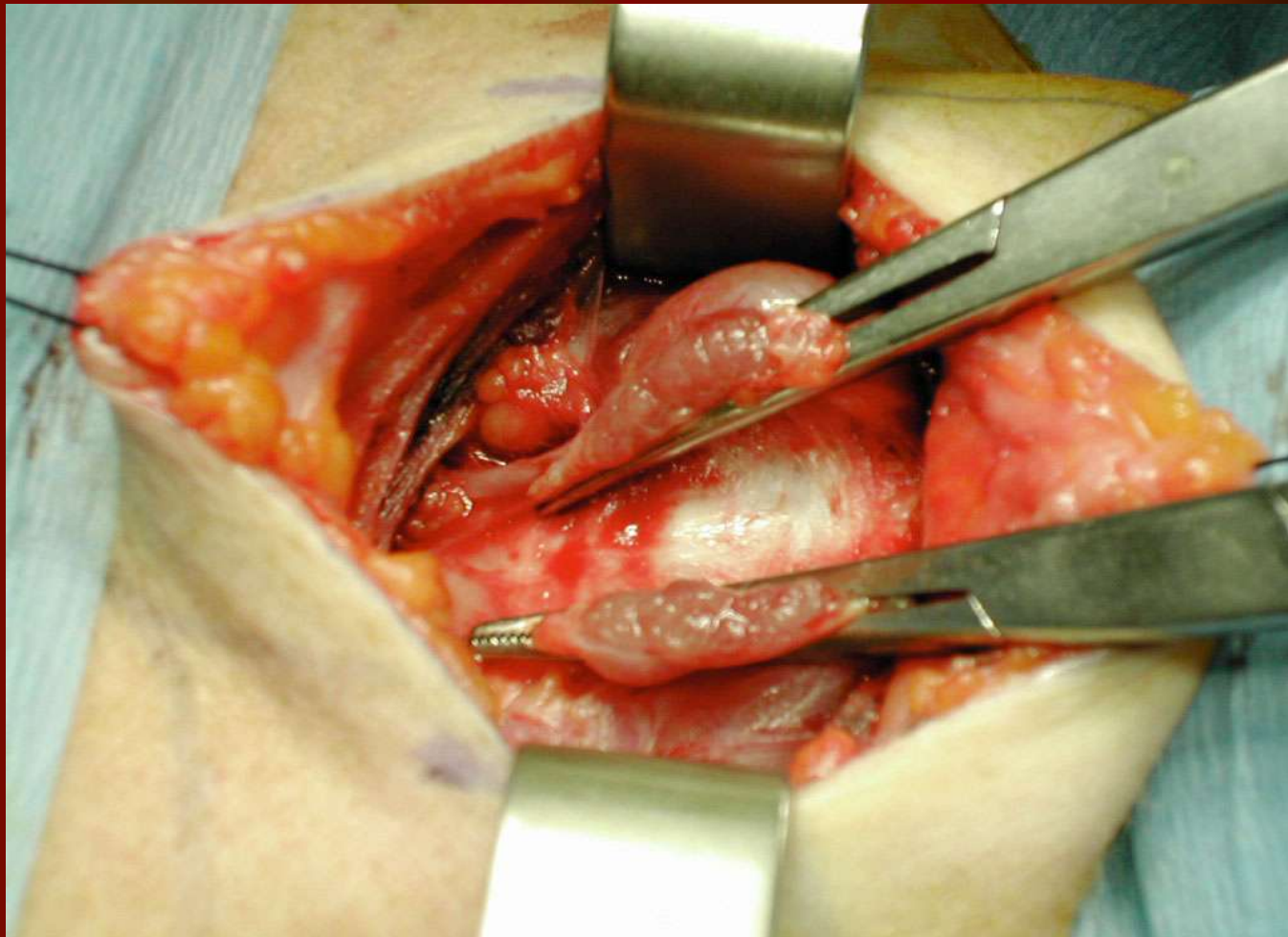
# CHIRURGIE THYROIDIENNE



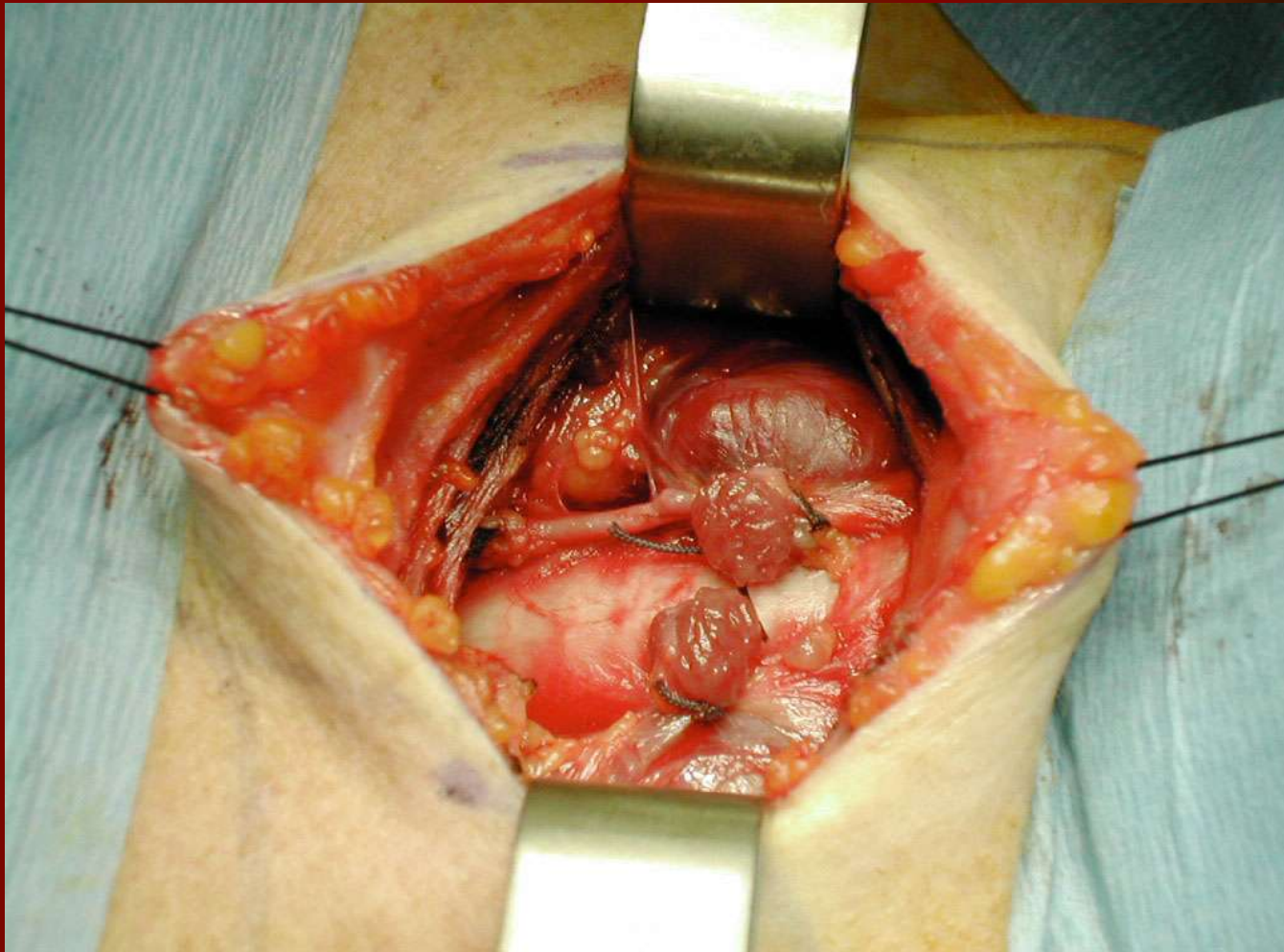
# CHIRURGIE THYROIDIENNE



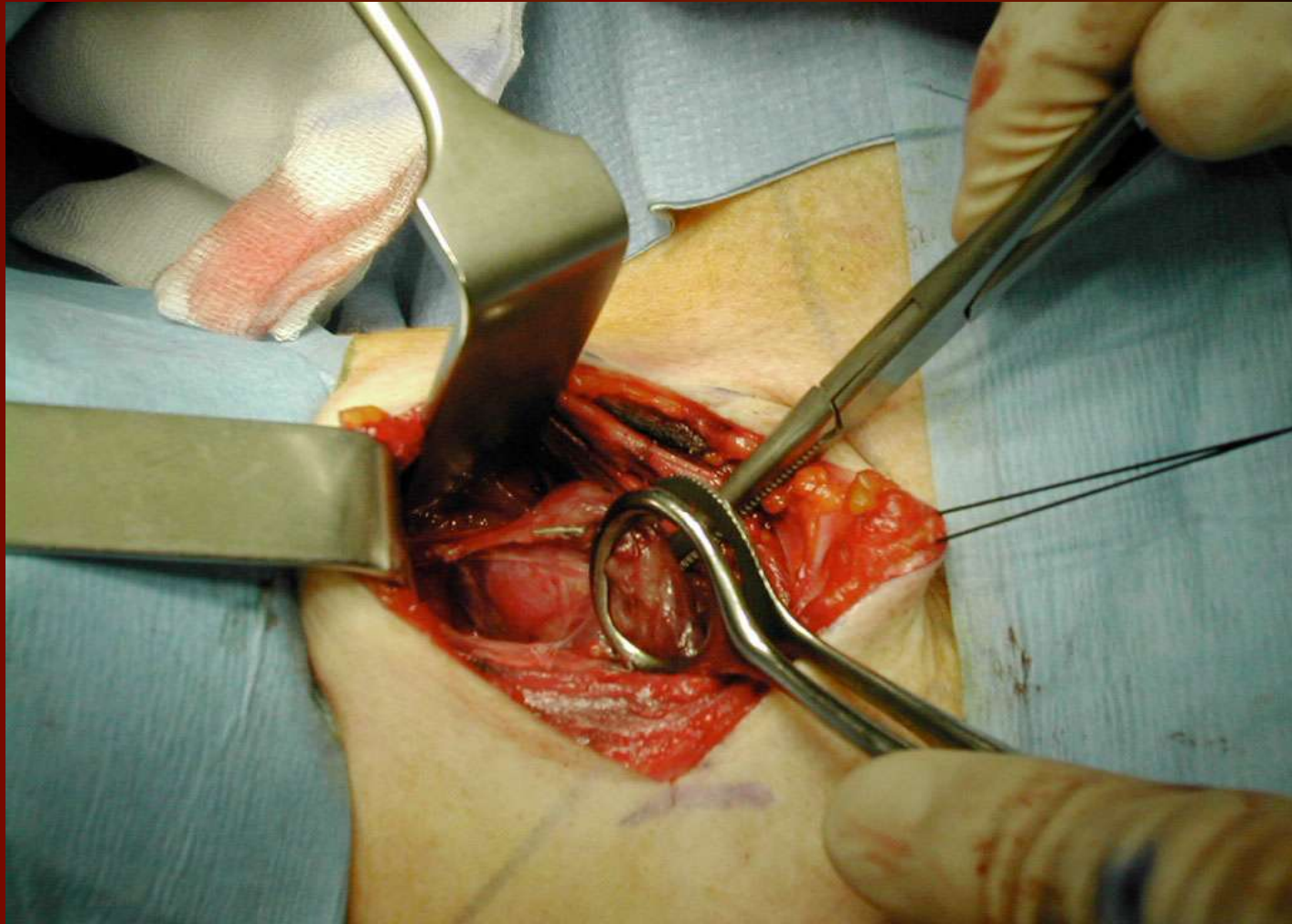
# CHIRURGIE THYROIDIENNE



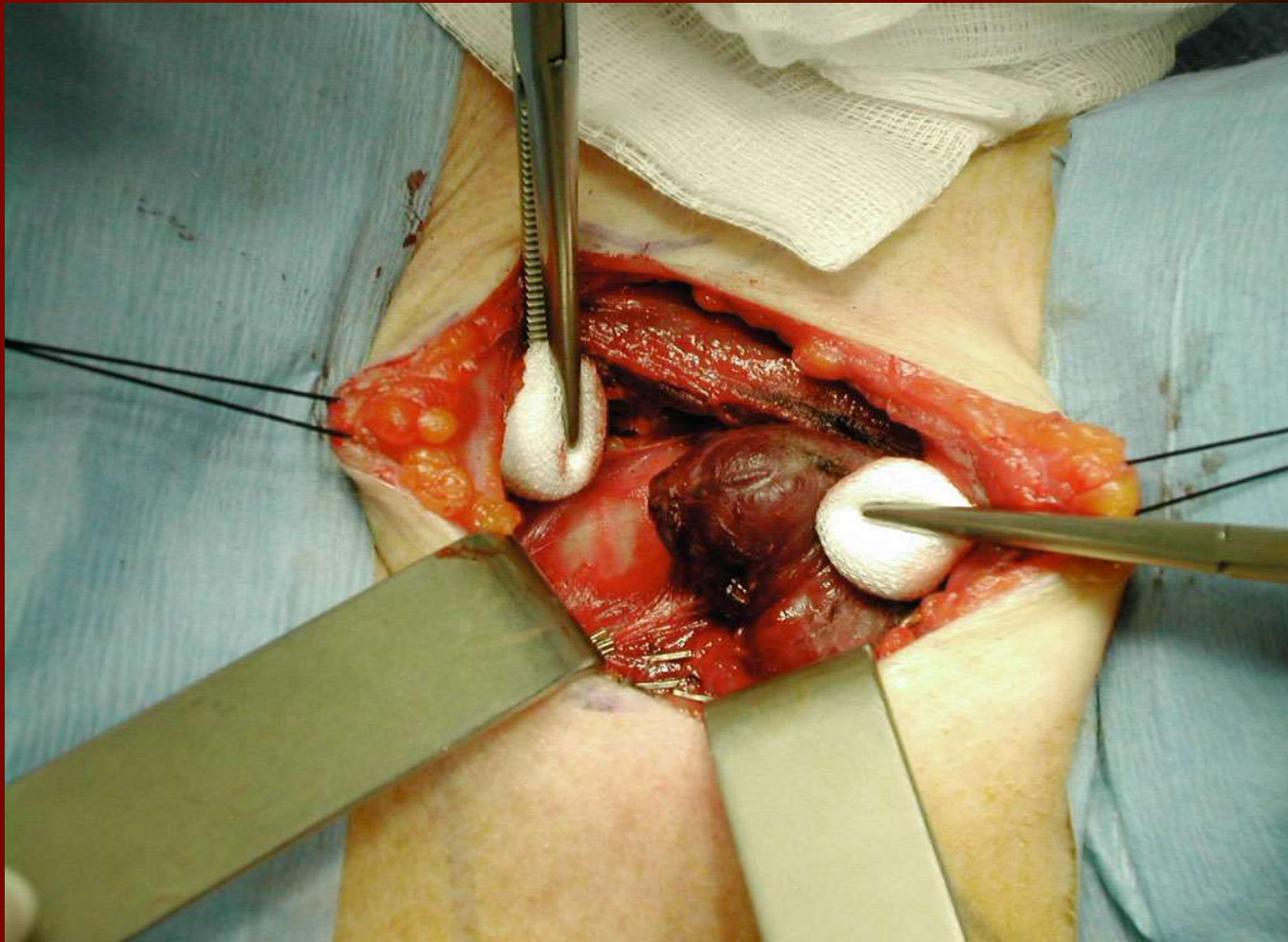
# CHIRURGIE THYROIDIENNE



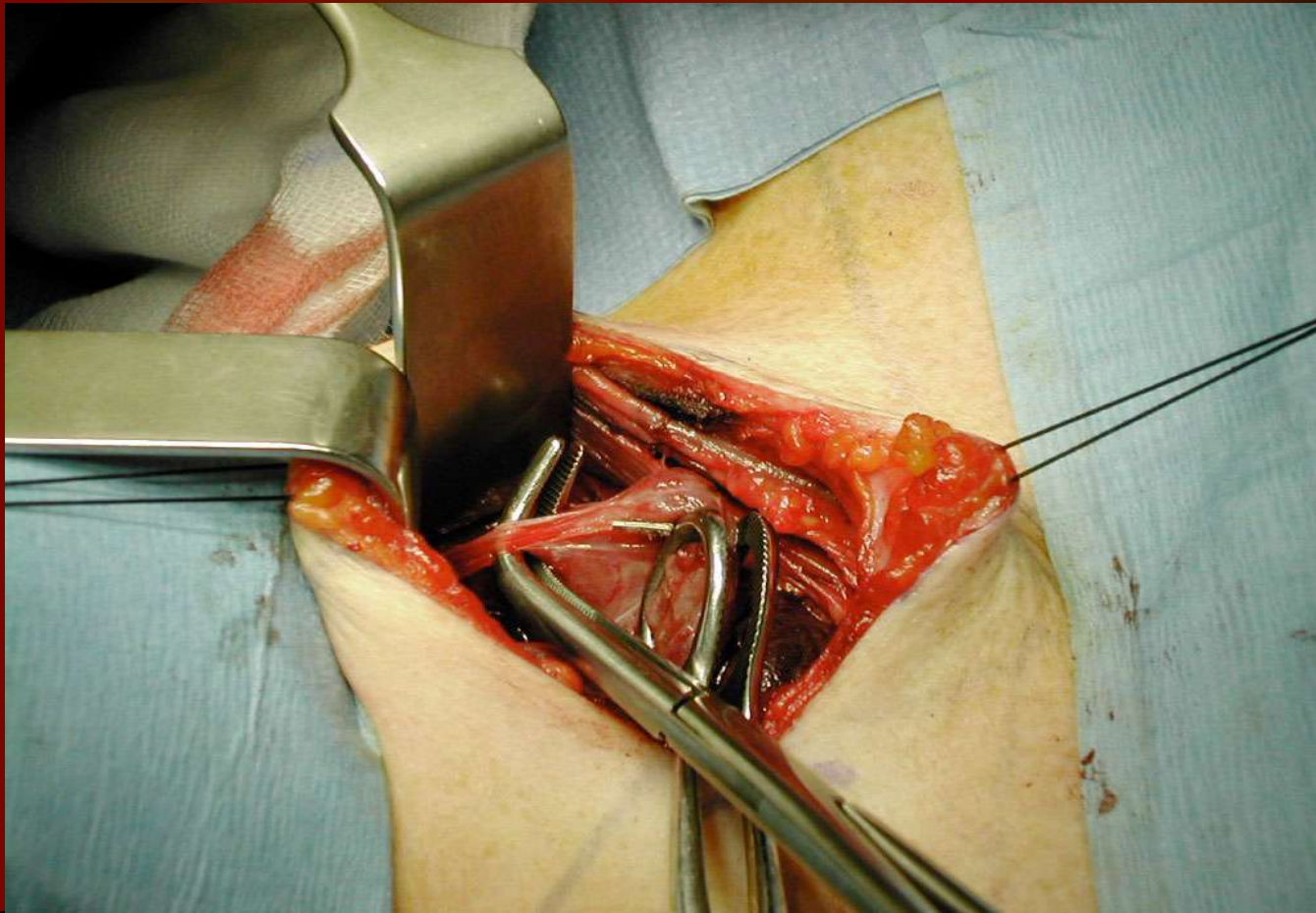
# CHIRURGIE THYROIDIENNE



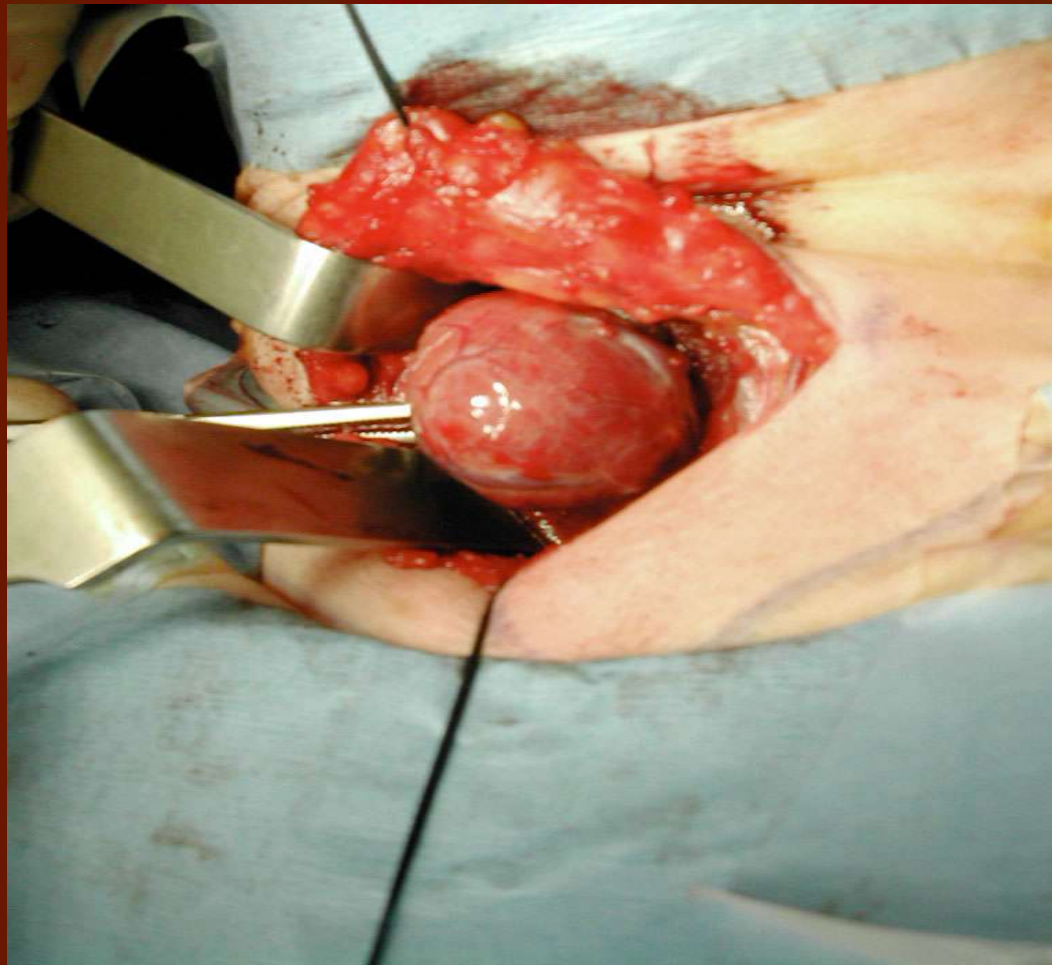
# CHIRURGIE THYROIDIENNE



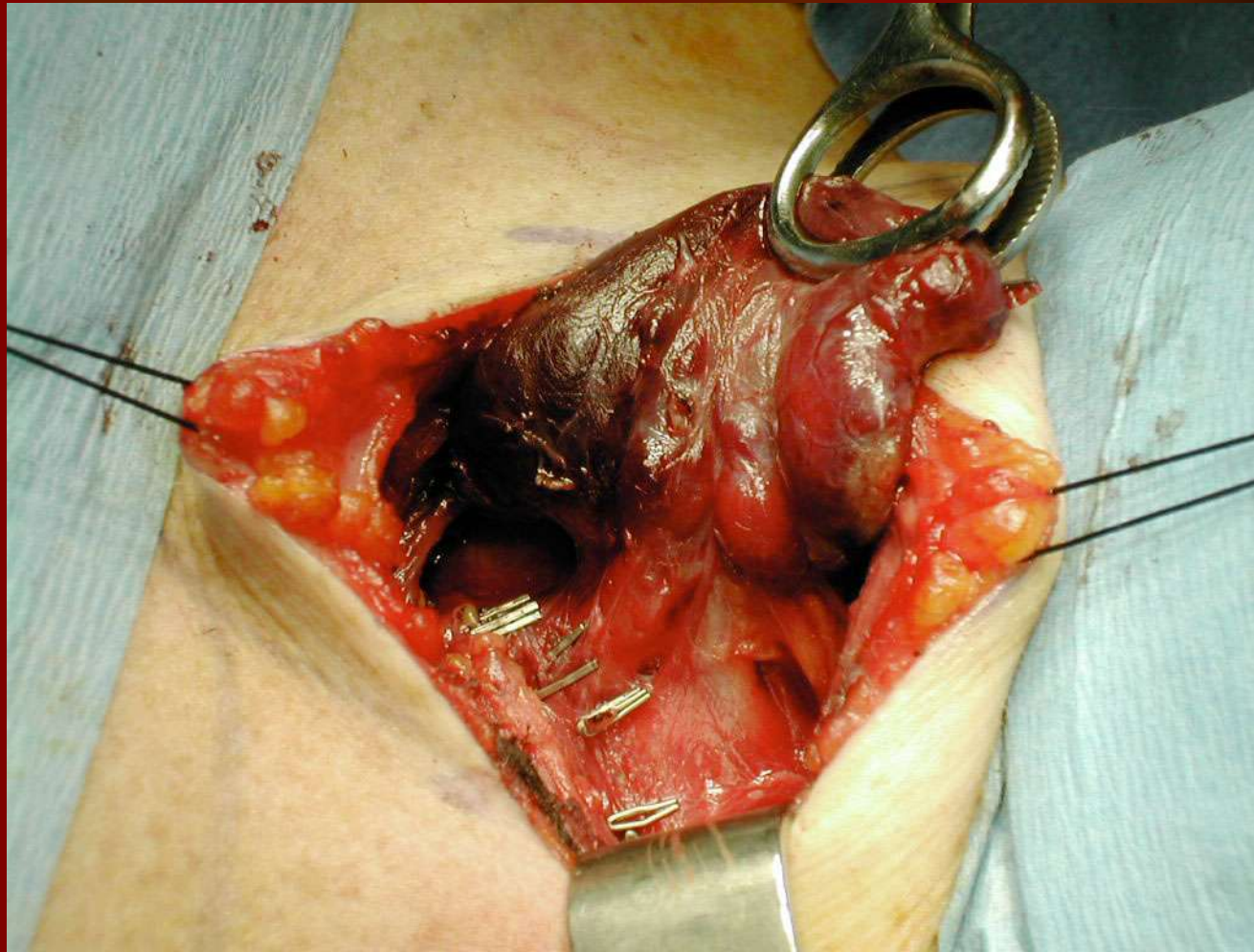
# CHIRURGIE THYROIDIENNE



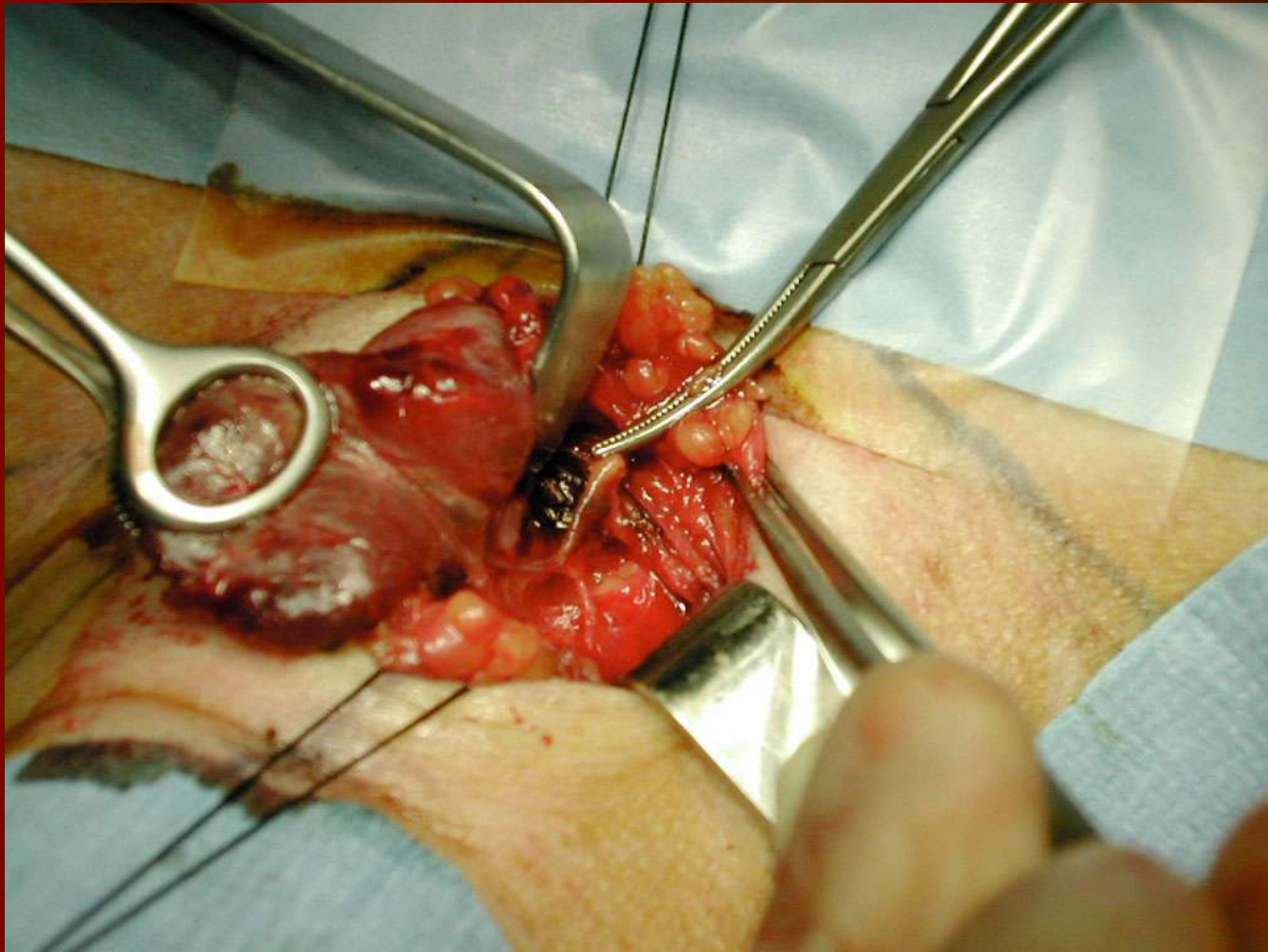
# CHIRURGIE THYROIDIENNE



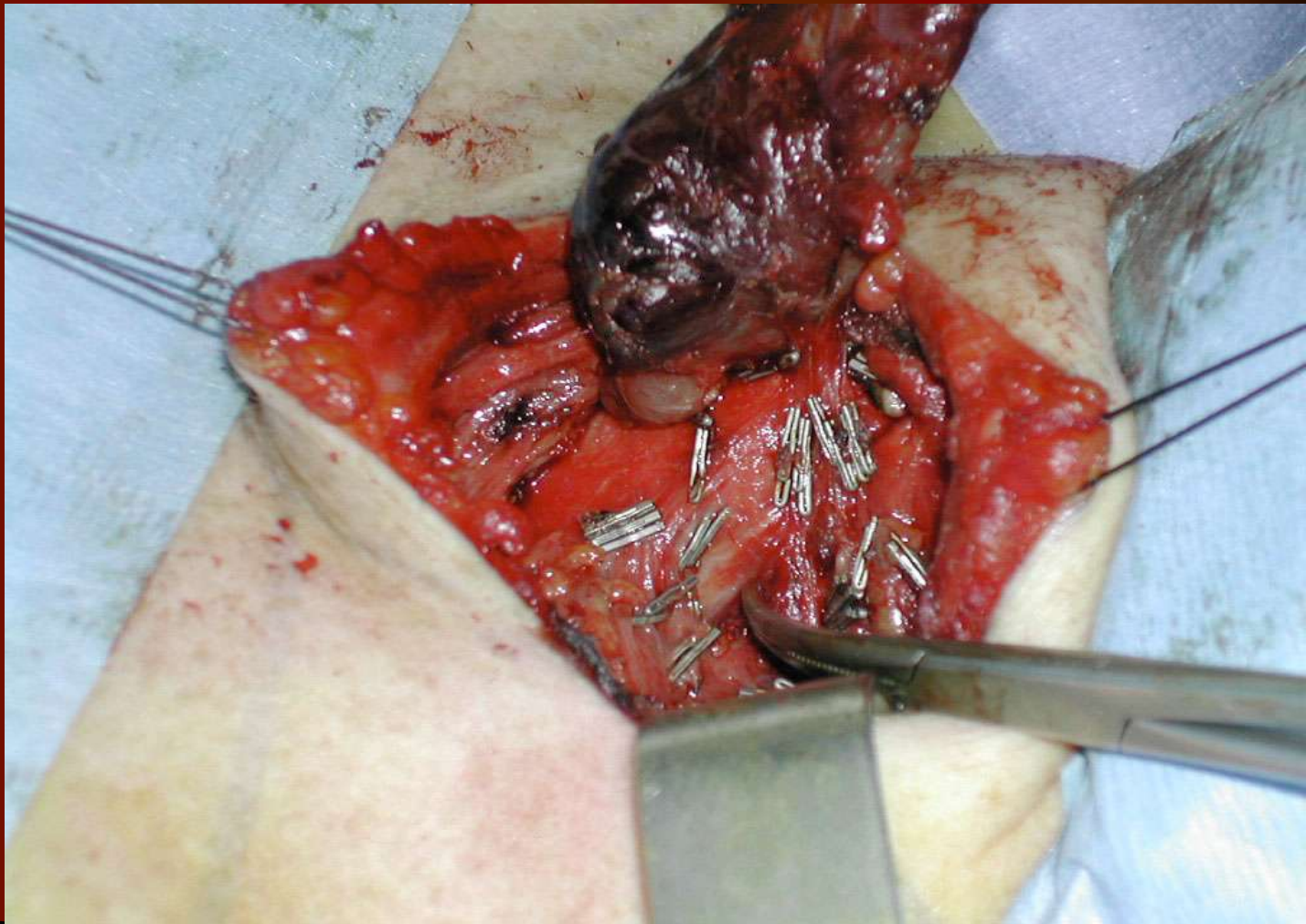# CHIRURGIE THYROIDIENNE




# CHIRURGIE THYROIDIENNE



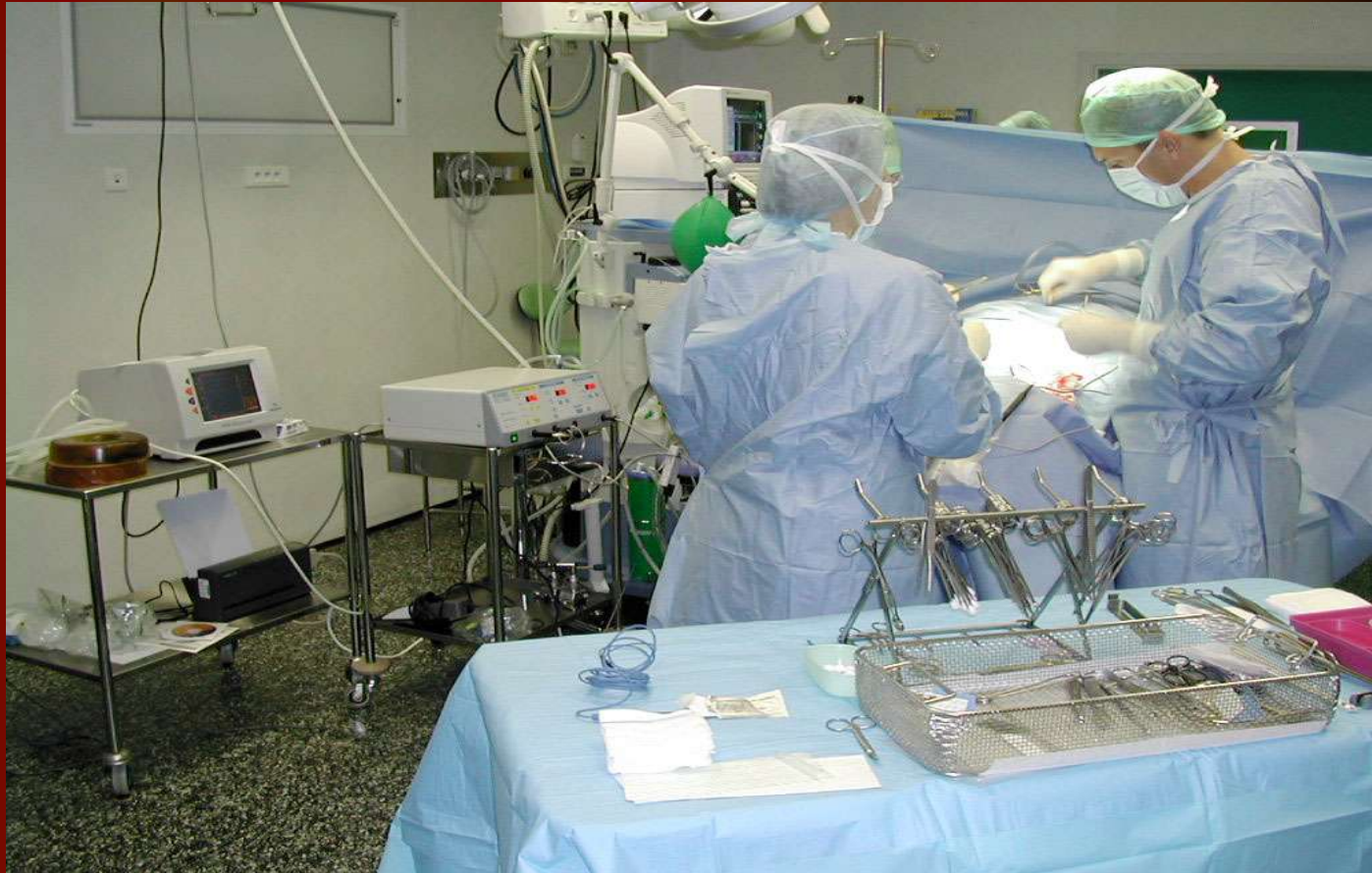# CHIRURGIE THYROIDIENNE



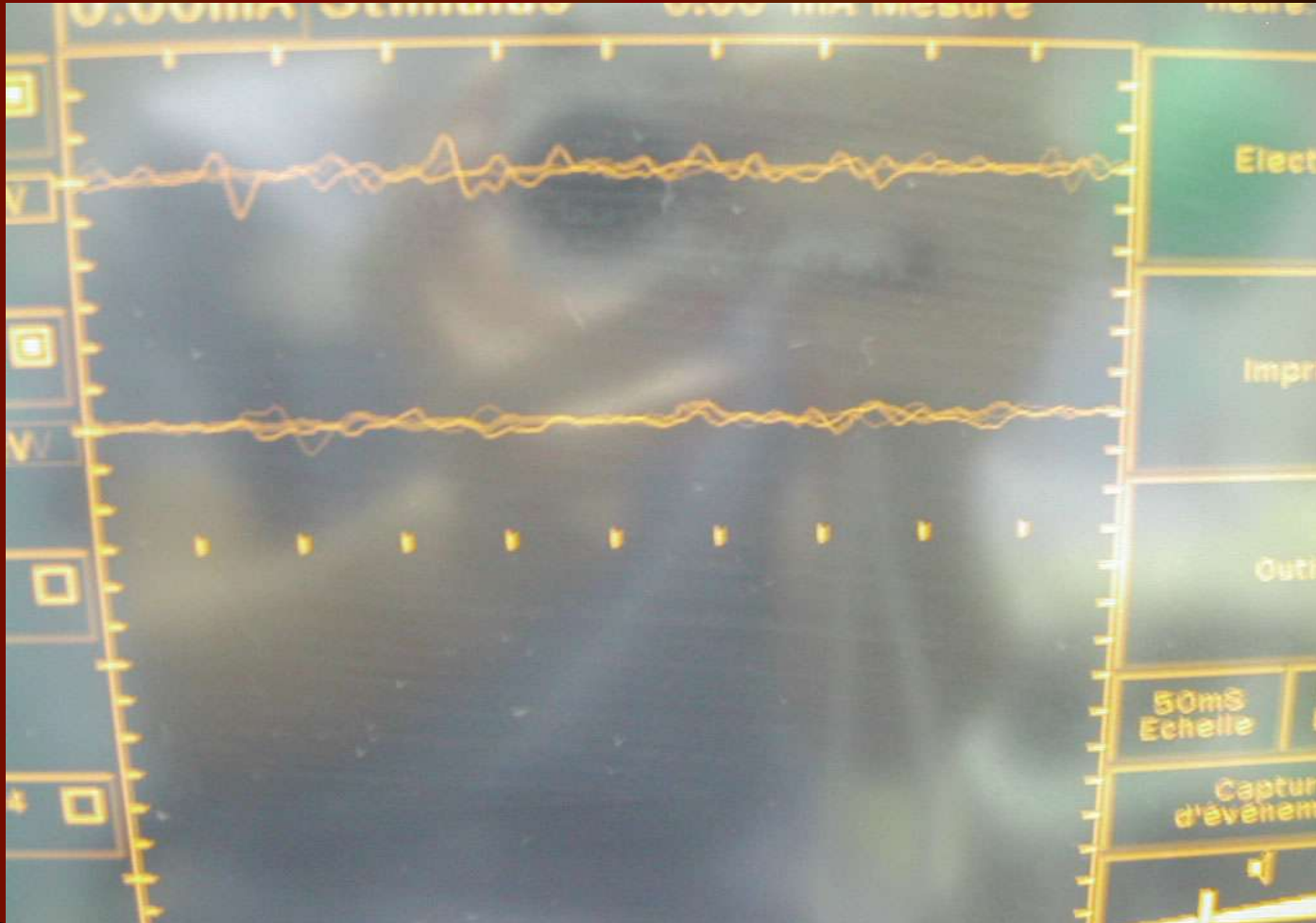
# CHIRURGIE THYROIDIENNE



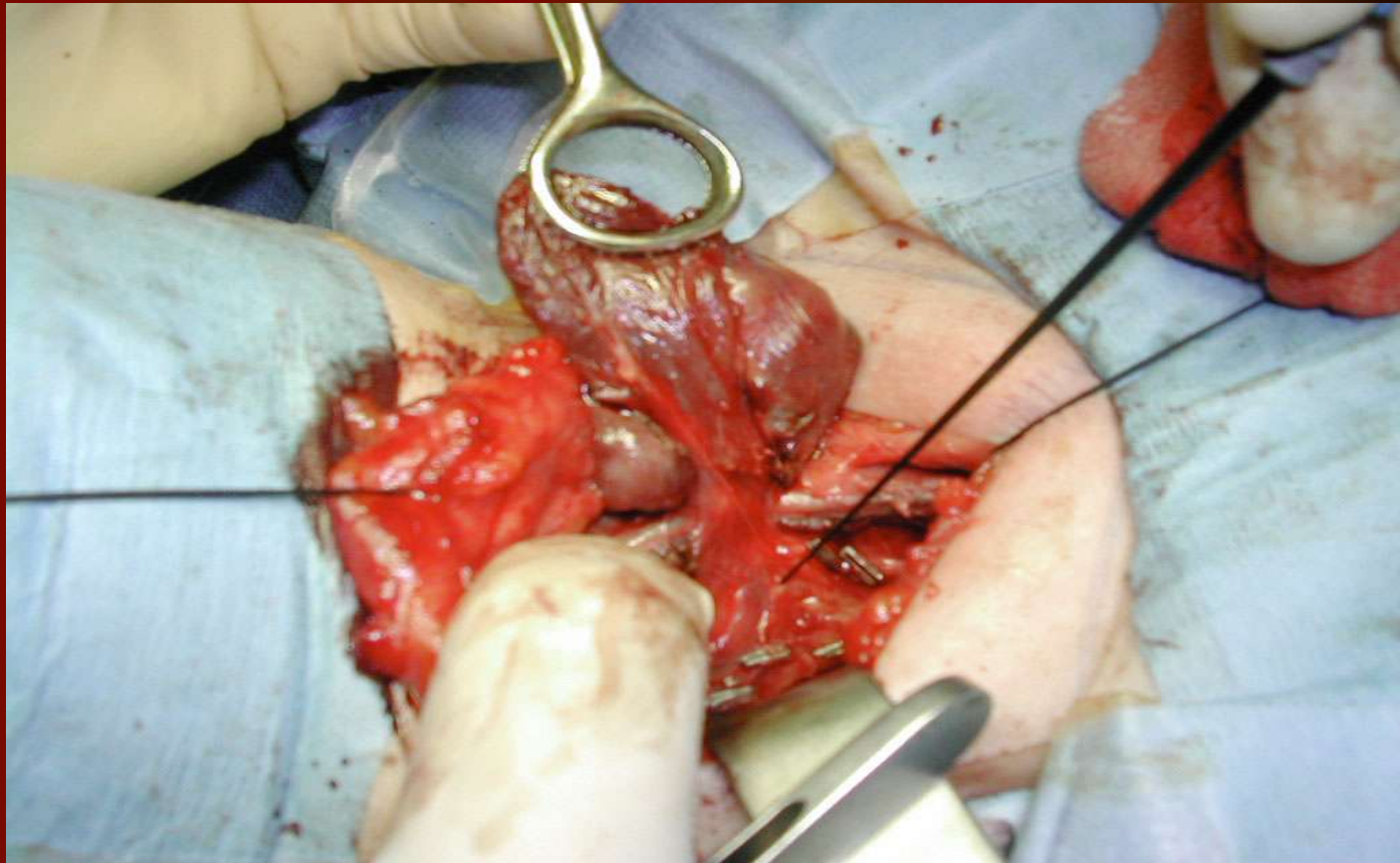
# CHIRURGIE THYROIDIENNE



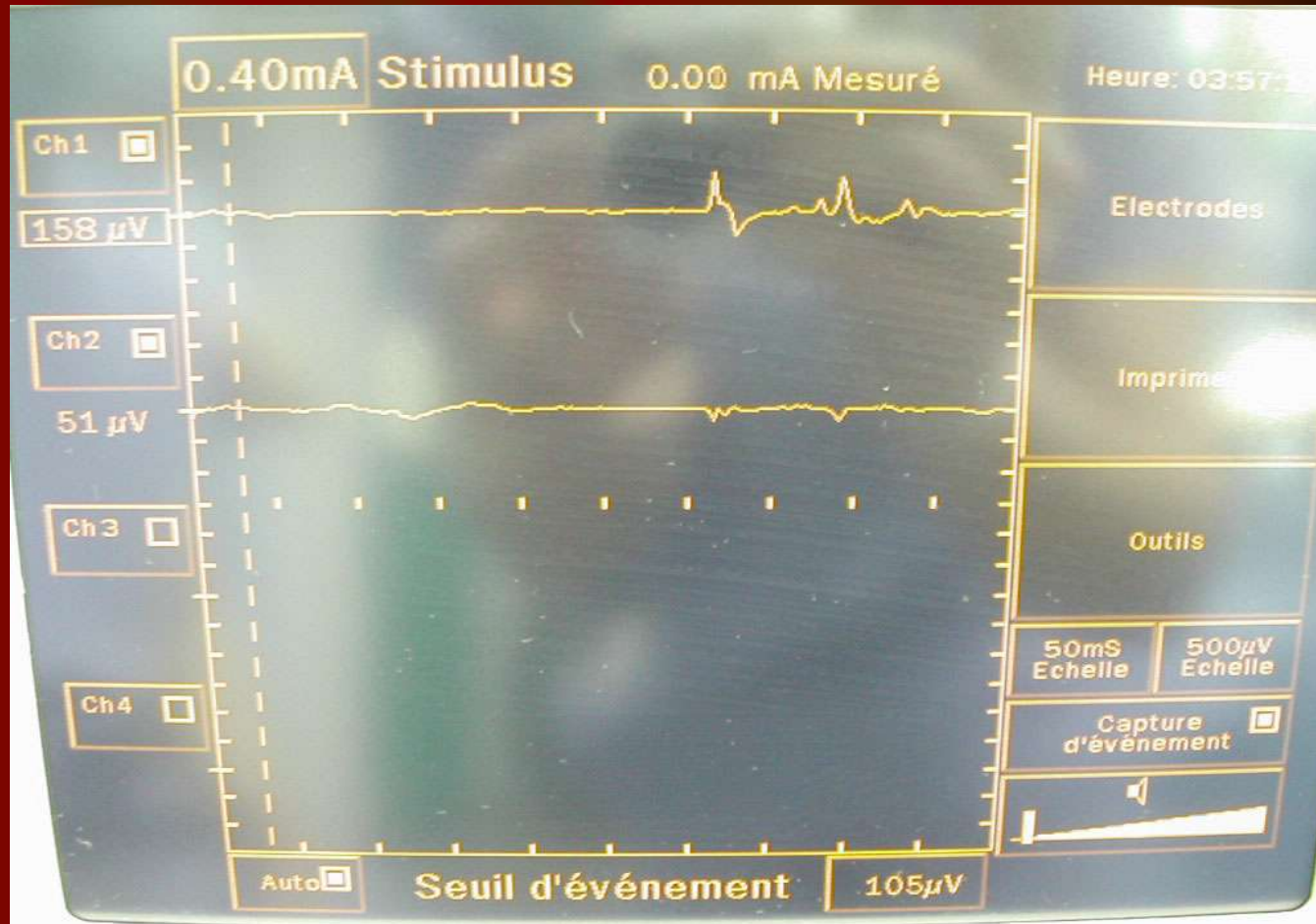# CHIRURGIE THYROIDIENNE



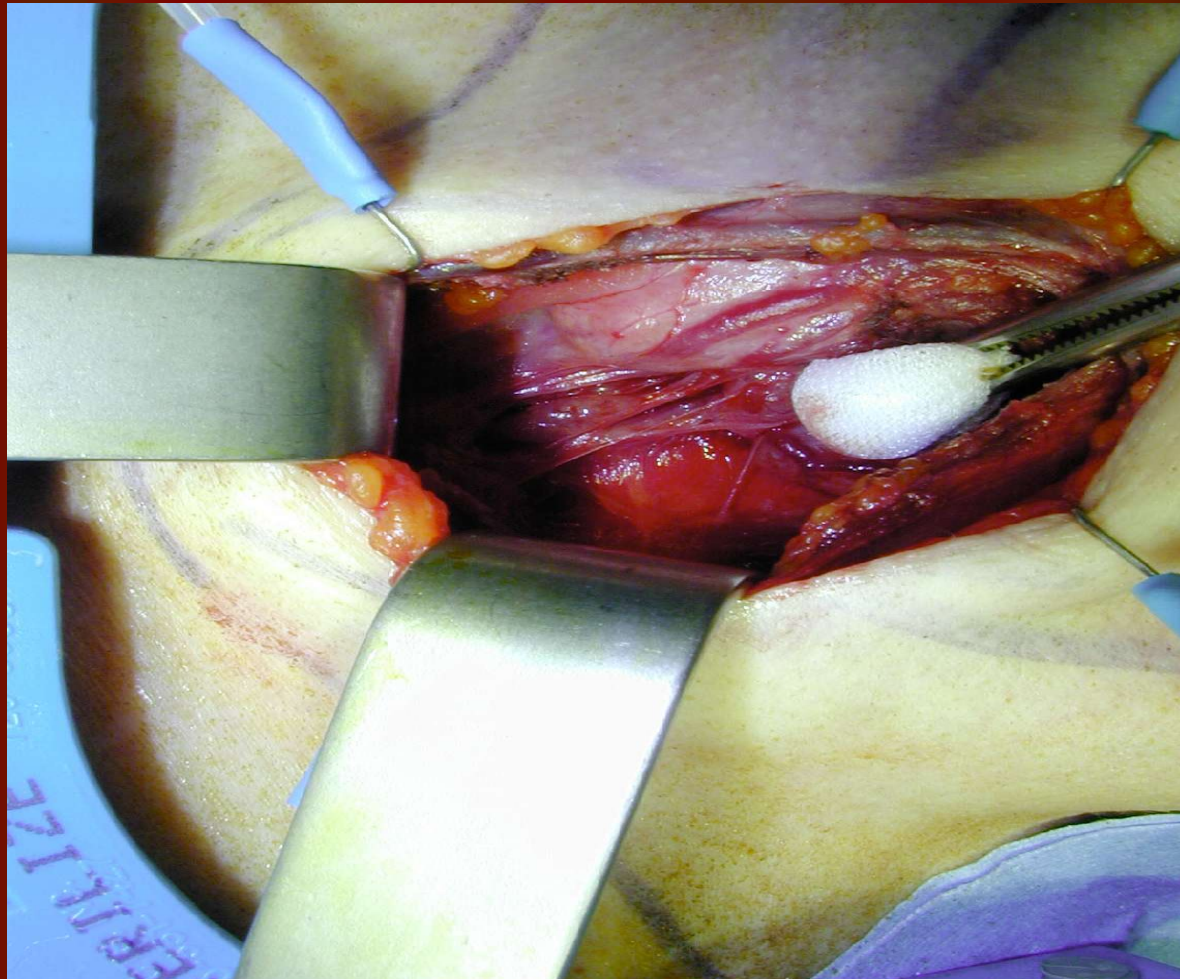
# CHIRURGIE THYROIDIENNE



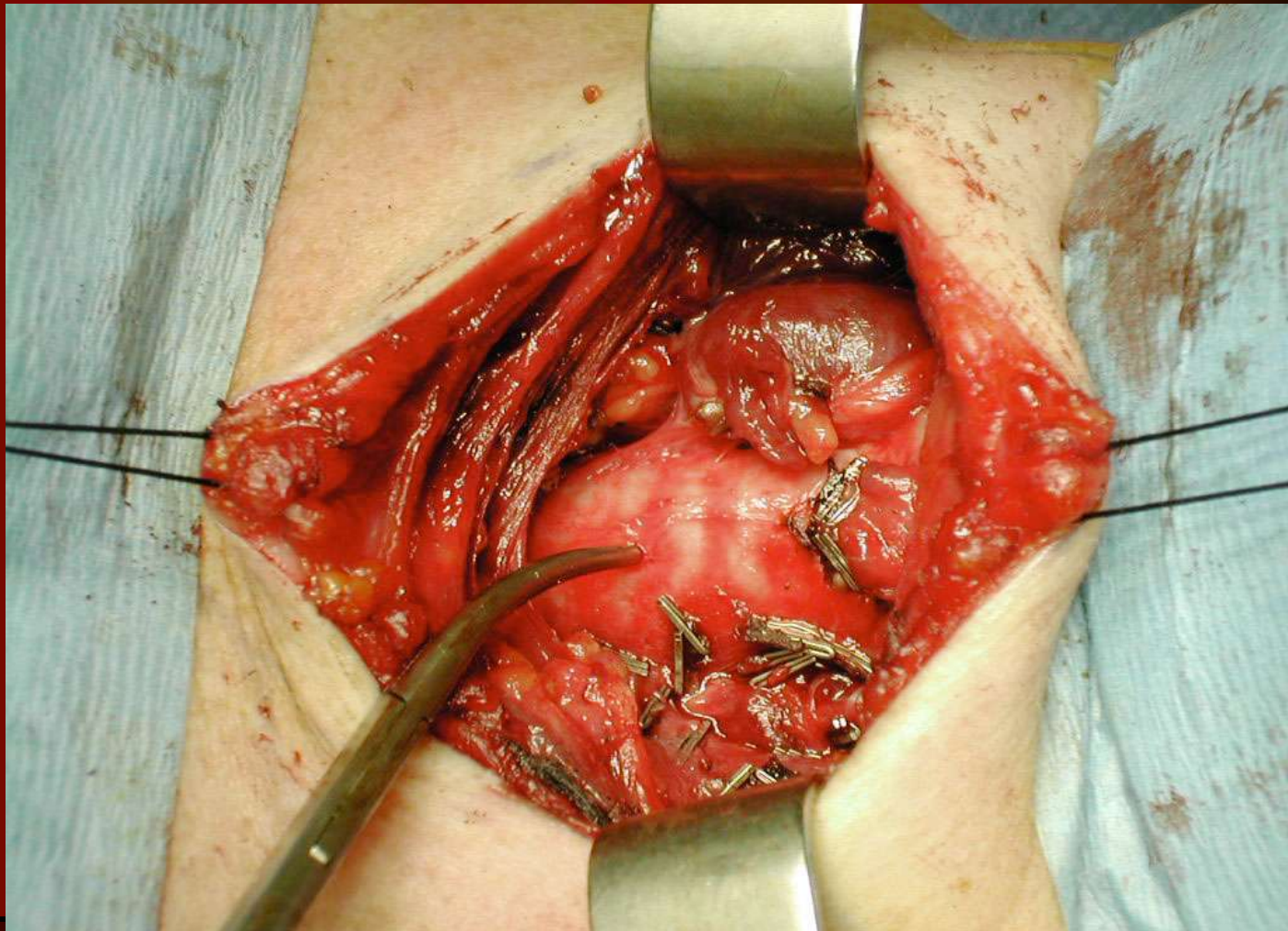
# CHIRURGIE THYROIDIENNE



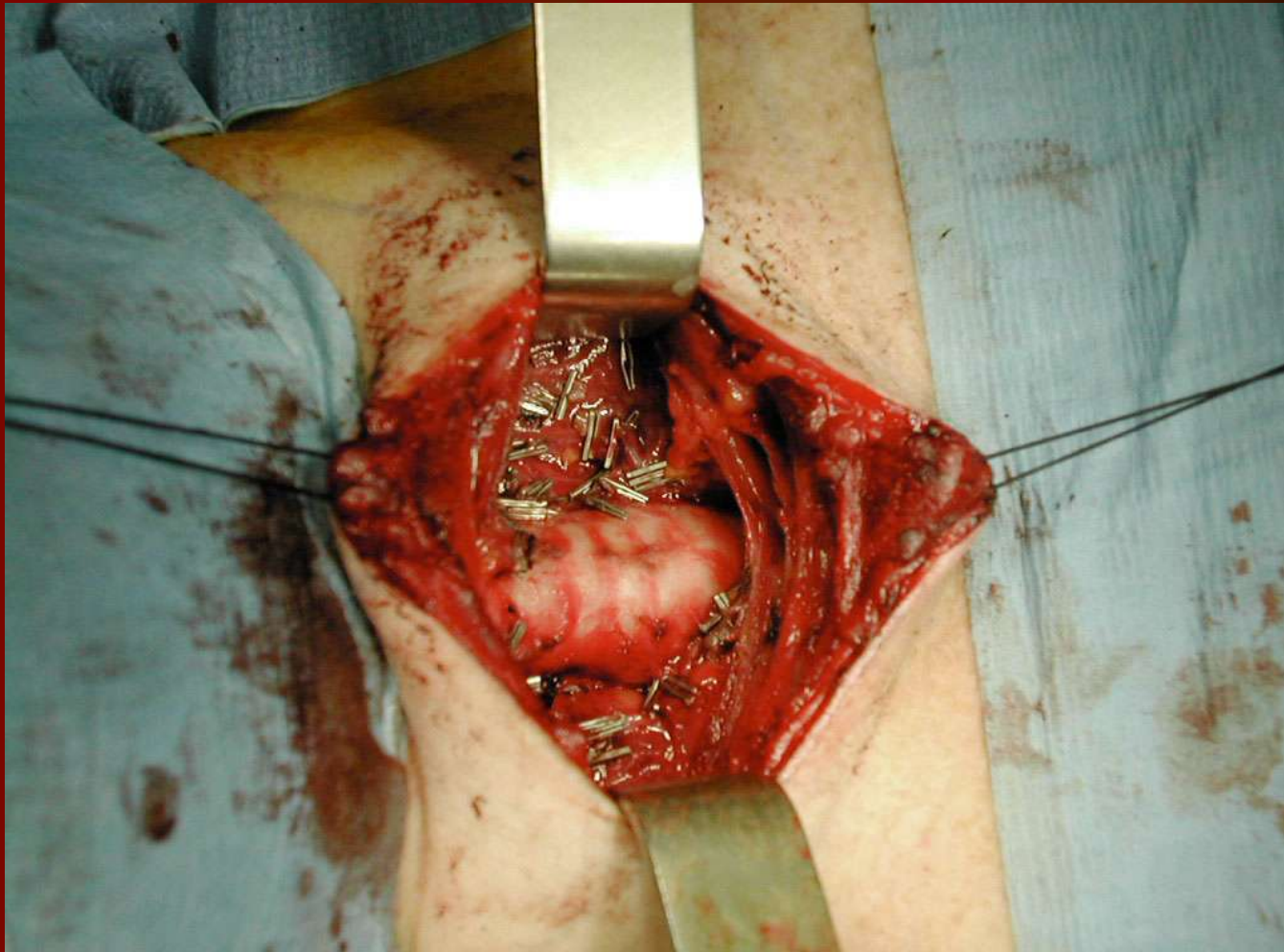
# CHIRURGIE THYROIDIENNE



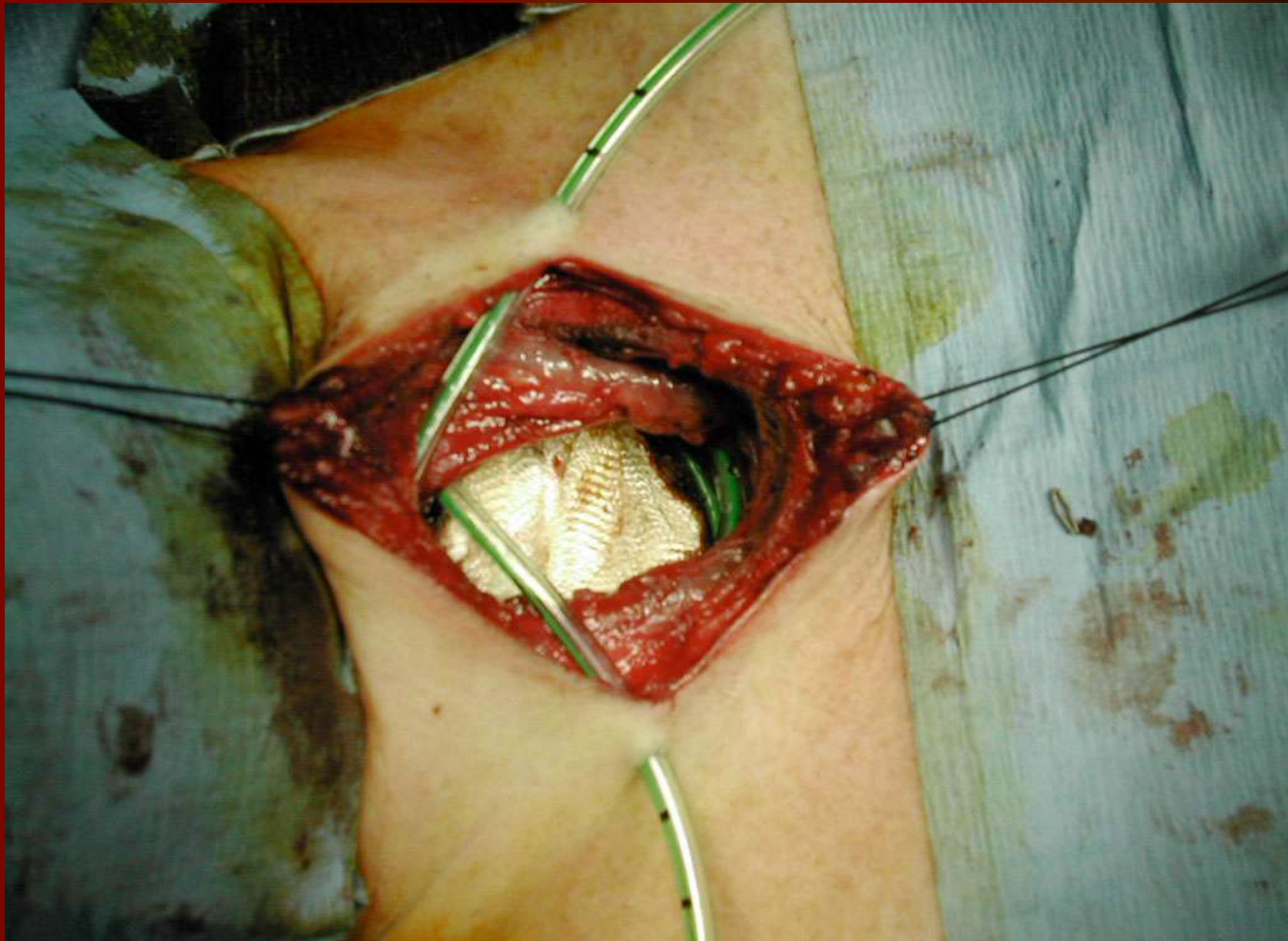
# CHIRURGIE THYROÏDIENNE



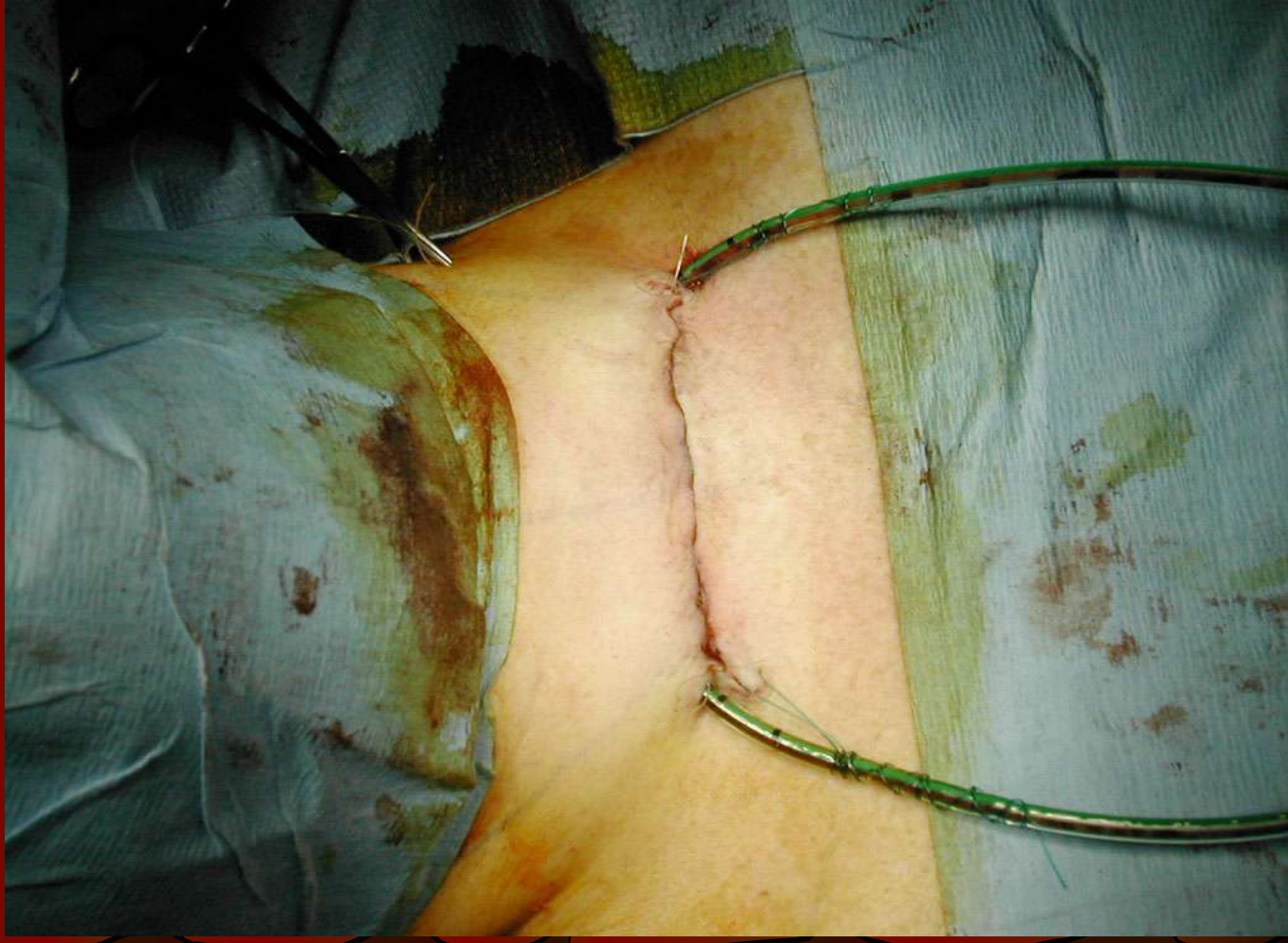# CHIRURGIE THYROIDIENNE



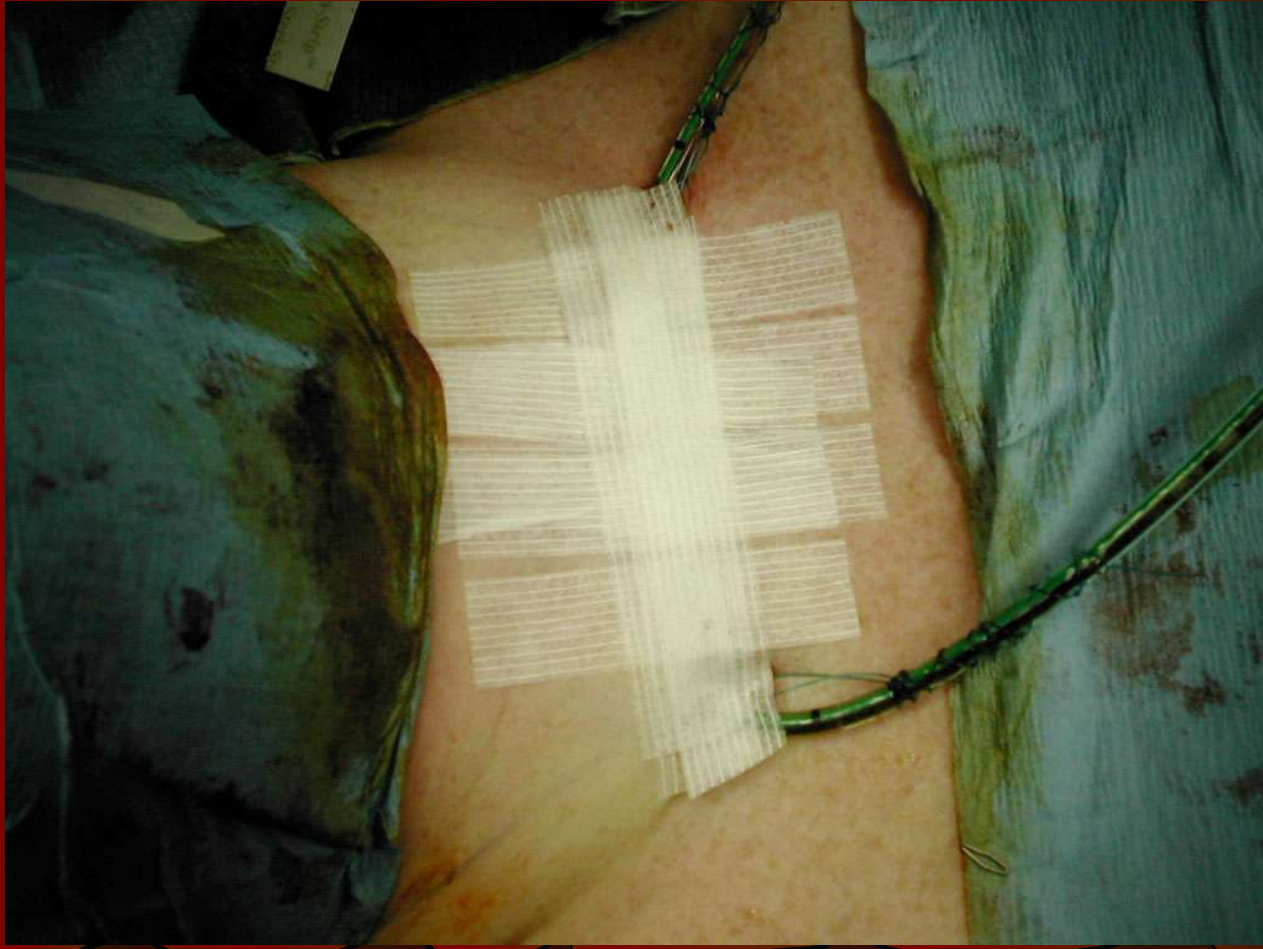
# CHIRURGIE THYROIDIENNE



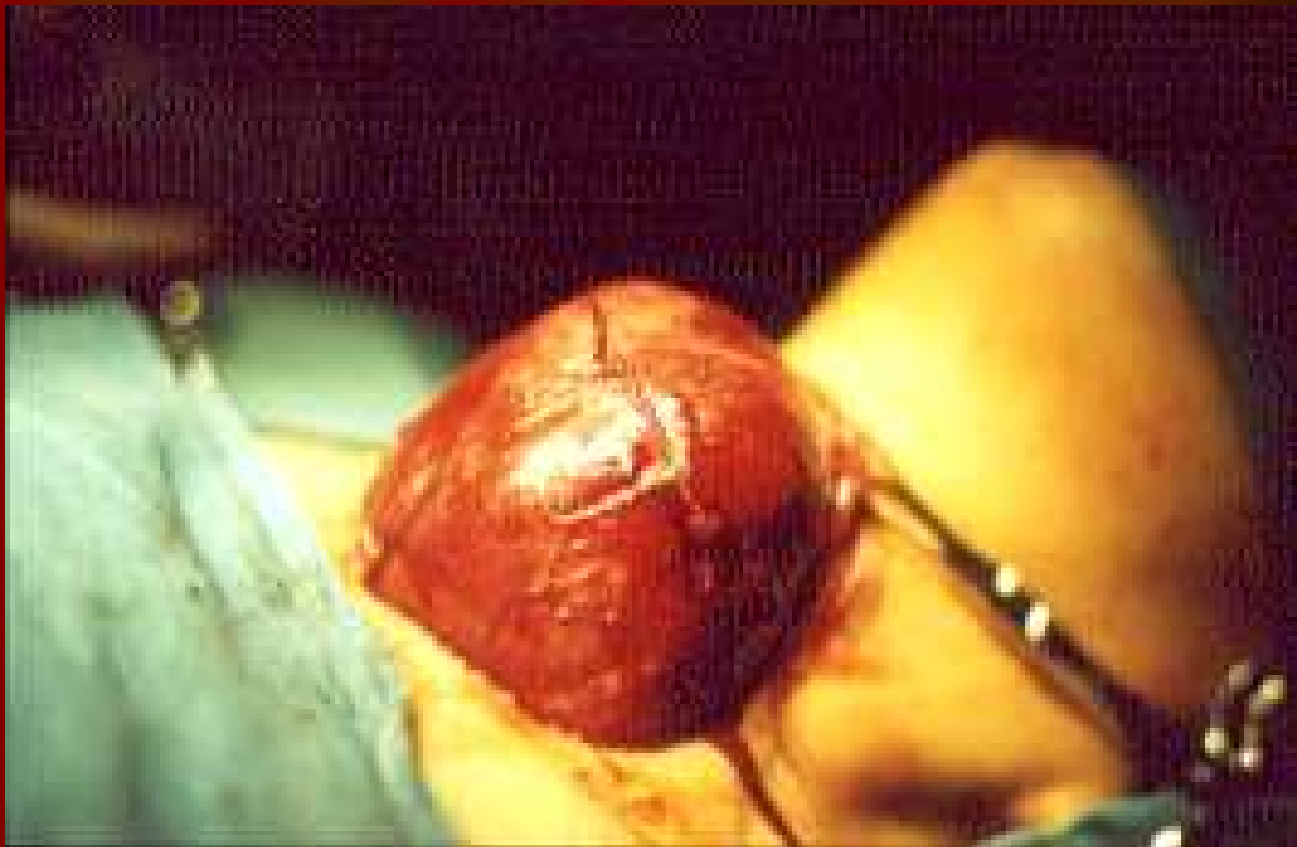# CHIRURGIE THYROIDIENNE

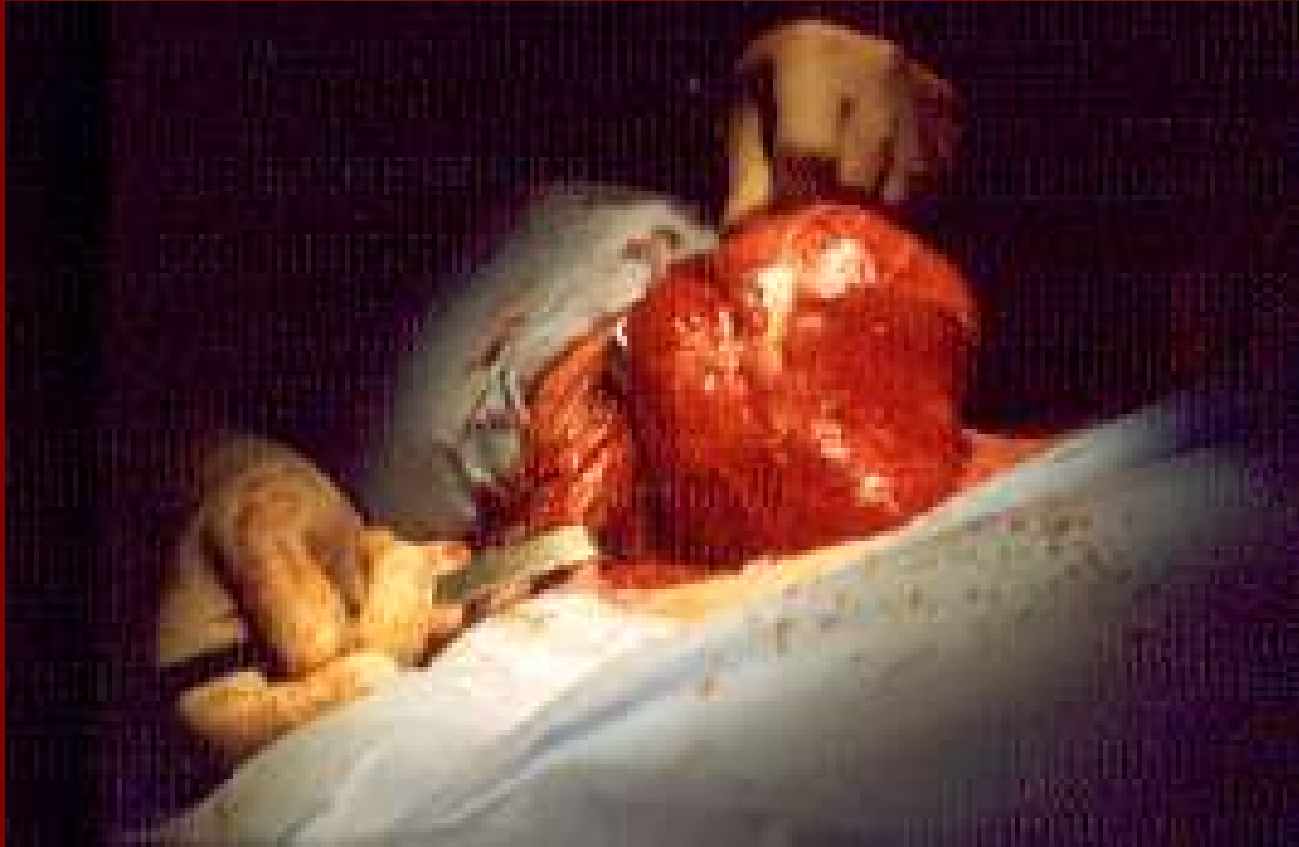


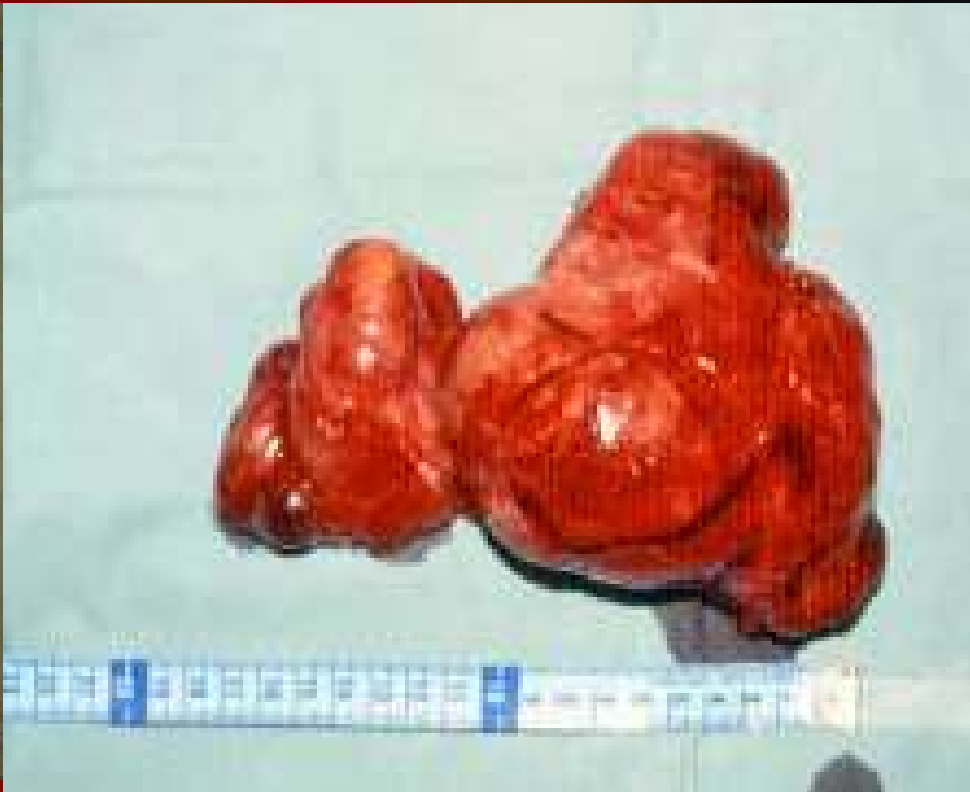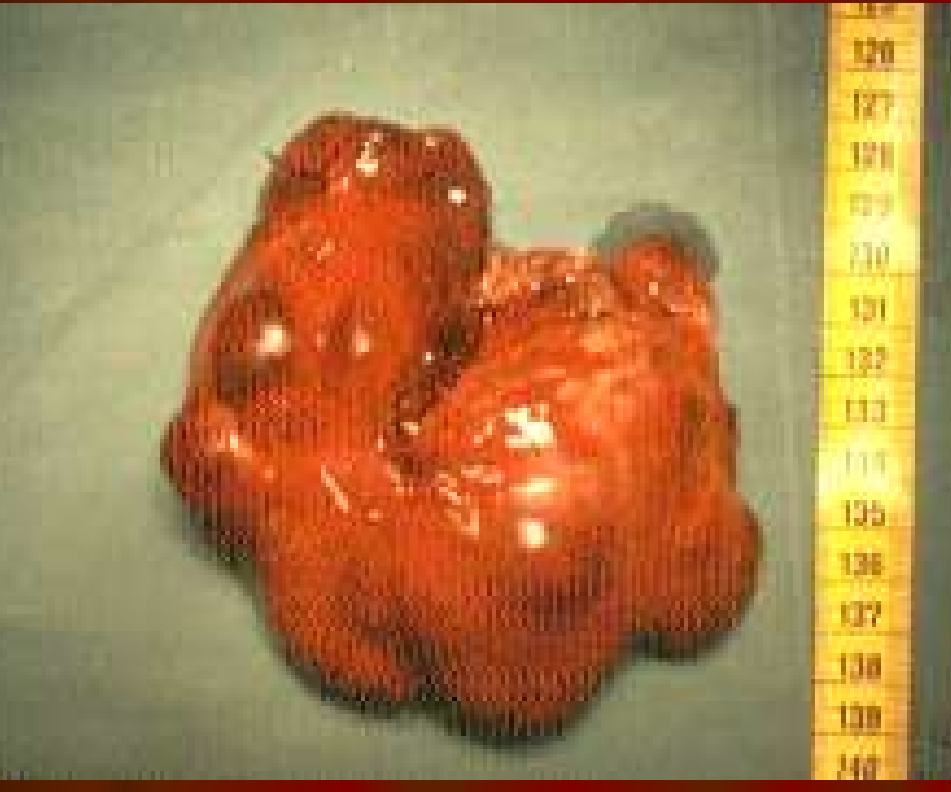
# CHIRURGIE THYROIDIENNE



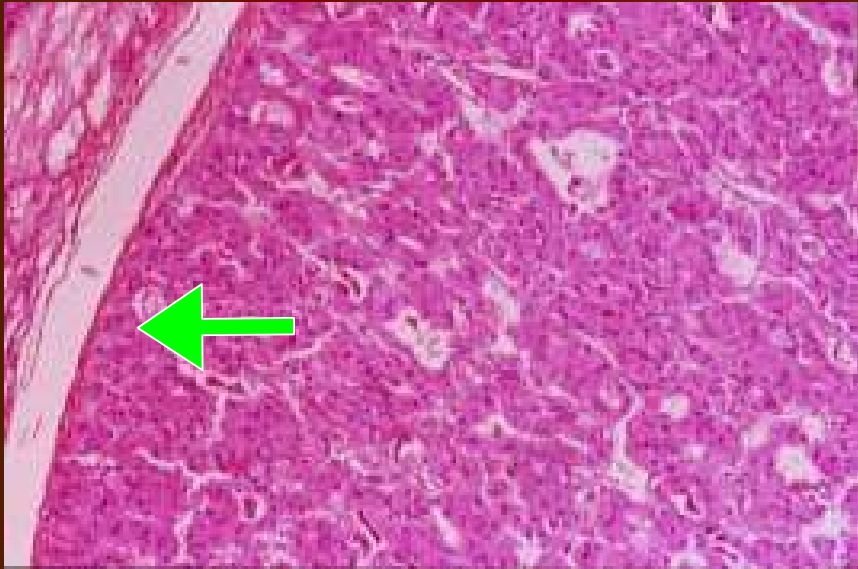









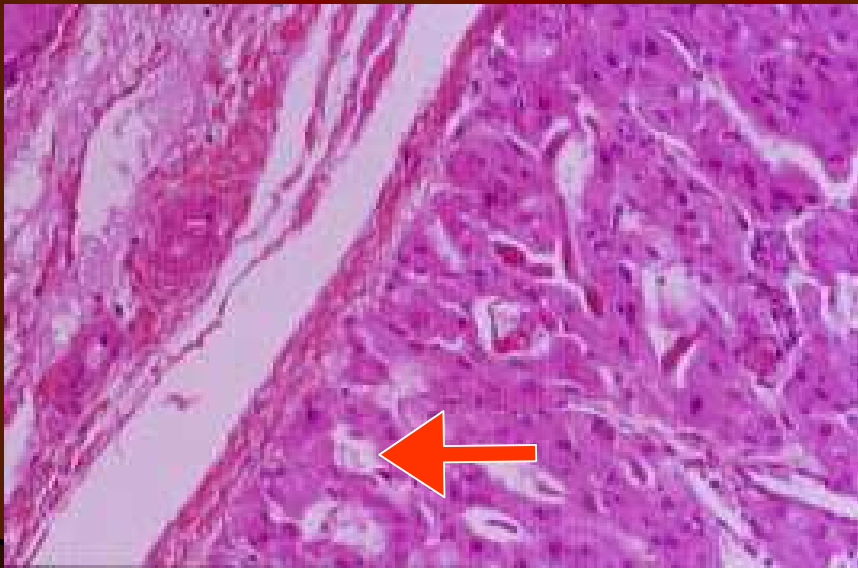
# Adénome Bénin



**Capsule  
fine**



***HES X 10***

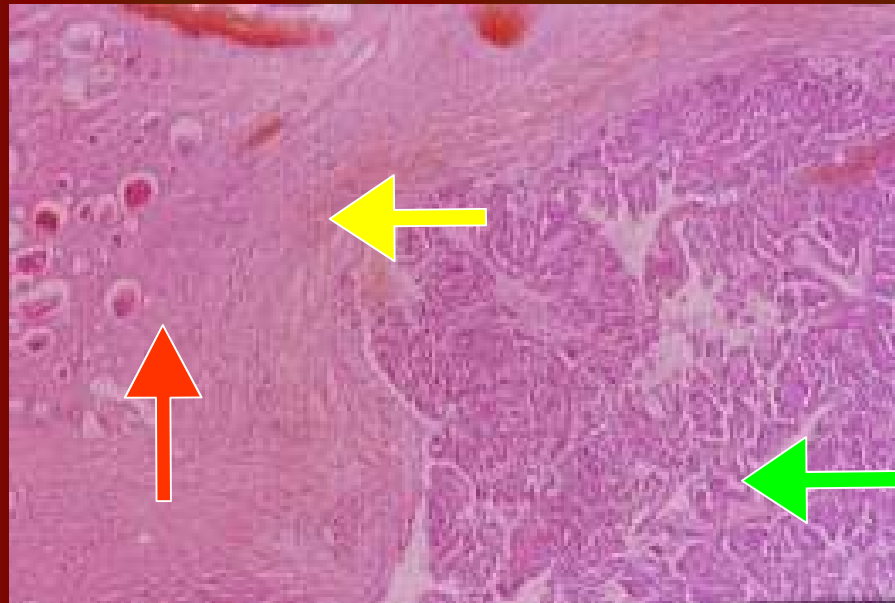


**Oncocyte = Cellules de  
Hürthle**




***HES X 20***

# Carcinome Papillaire



*HES X 5*



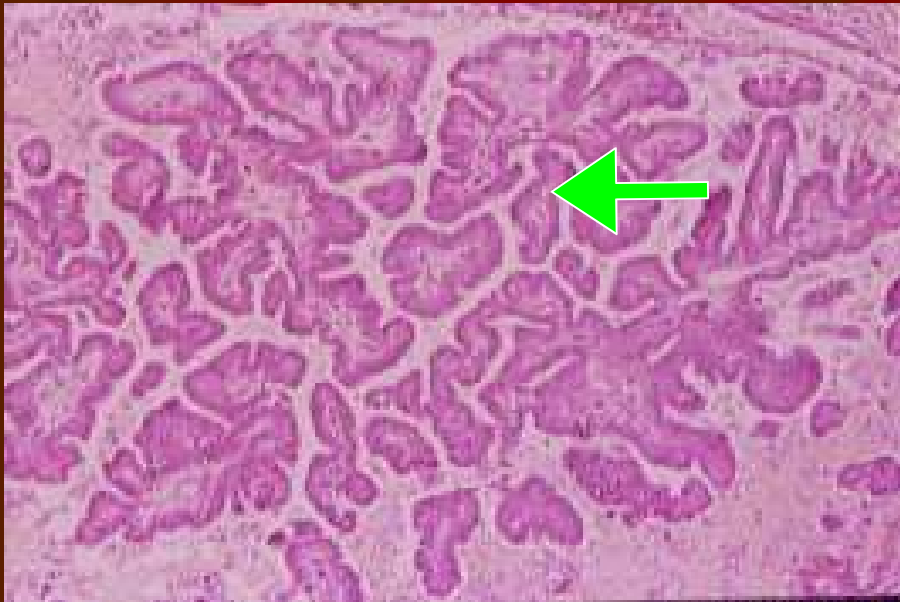
**Tumeur**



**Vésicules thyroïdiennes  
péritumorales**

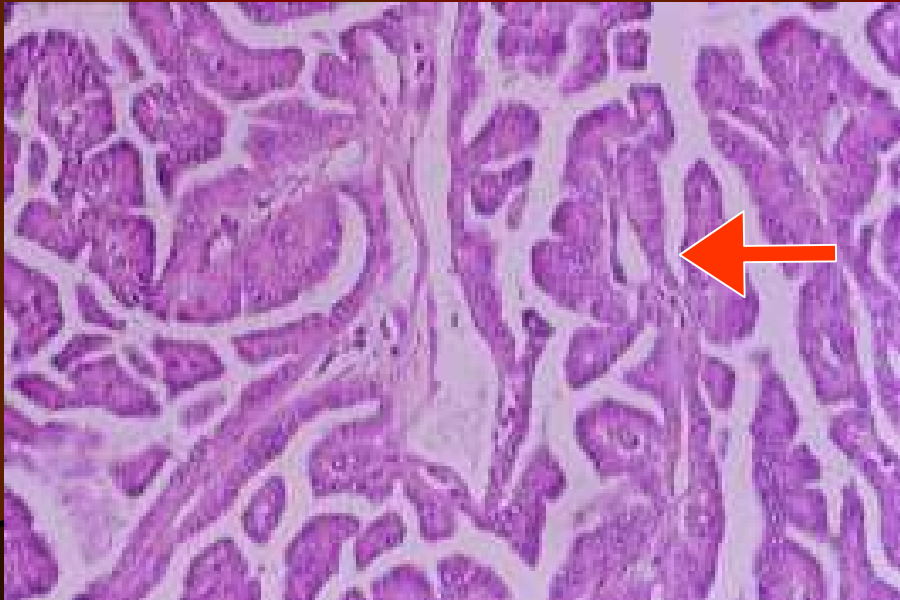


**Forte capsule scléreuse**



**Axe  
papillaire** ←

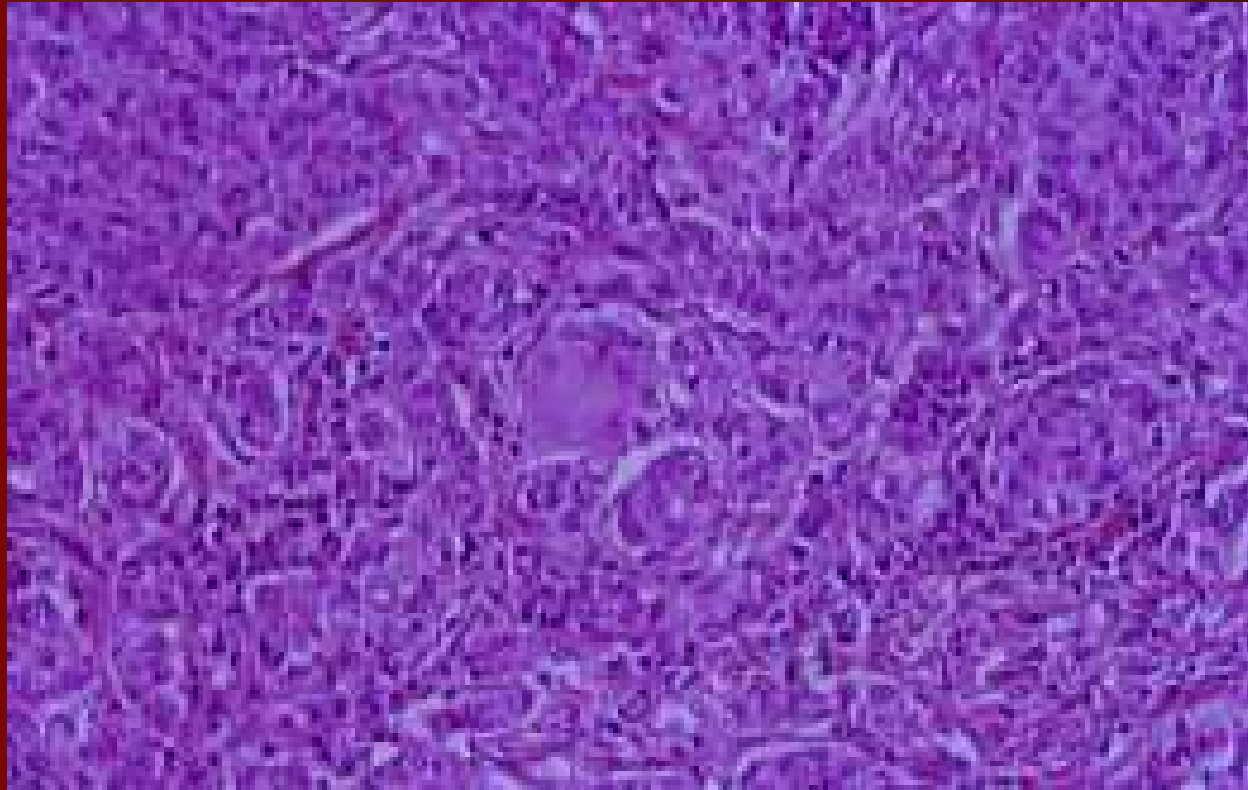
**HES X 10**



**Cellules  
tumoraux** ←

**HES X 20**

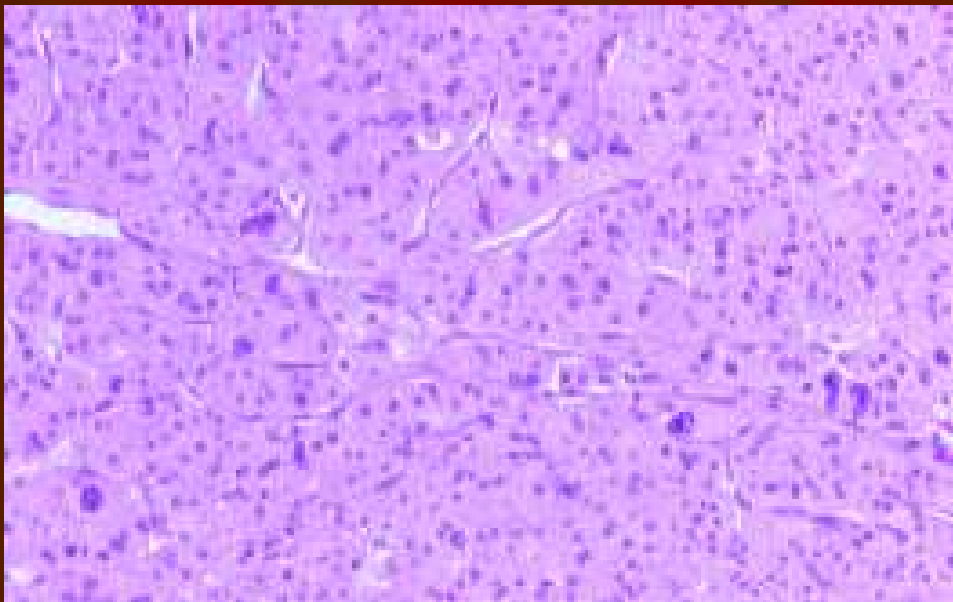
# Carcinome Anaplasique Thyroïdien



Cellules géantes tumorales plurinucléés

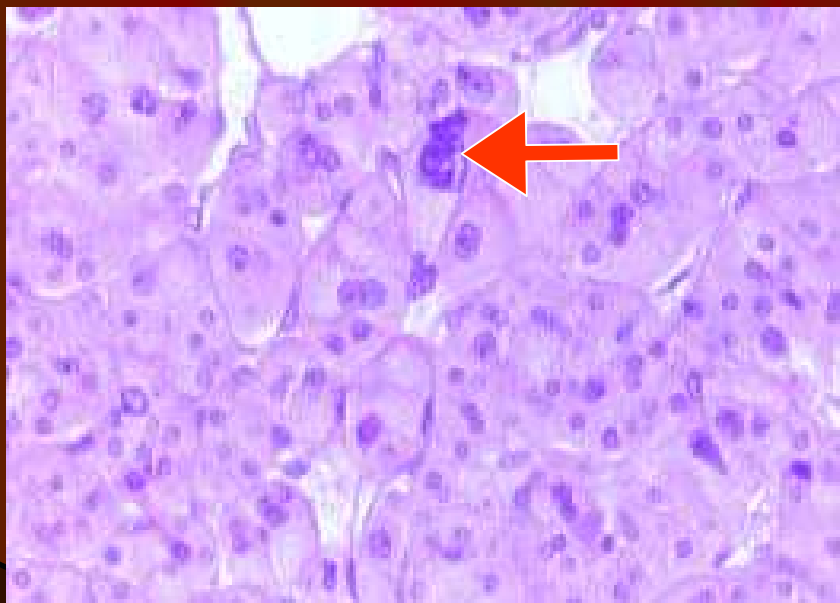
***HES X 20***

# **Carcinome à Cellules Oxyphiles**



Travées de cellules  
carcinomateuses oxyphiles

*HES X 20*

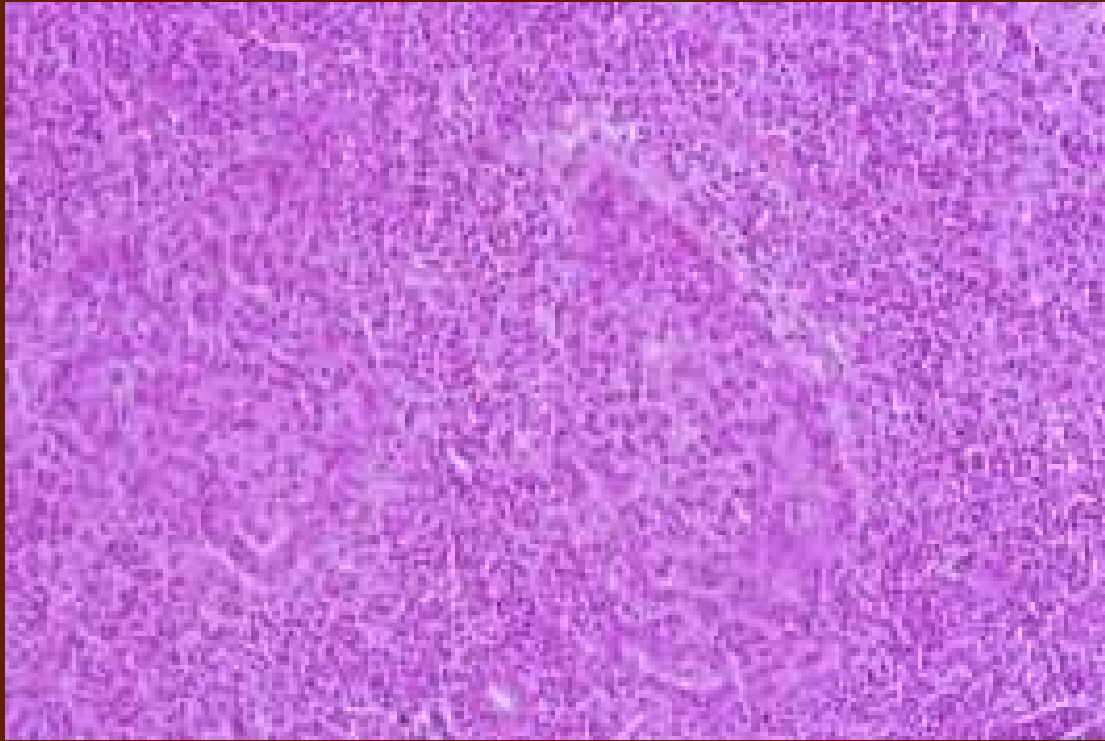


Noyau atypique



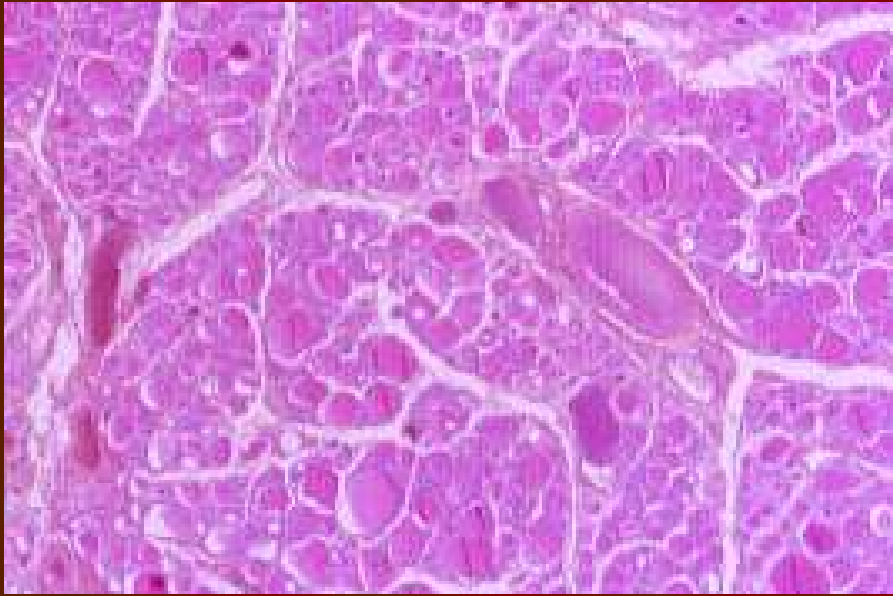
*HES X 40*

# Lymphome Malin Non Hodgkinien Thyroïdien

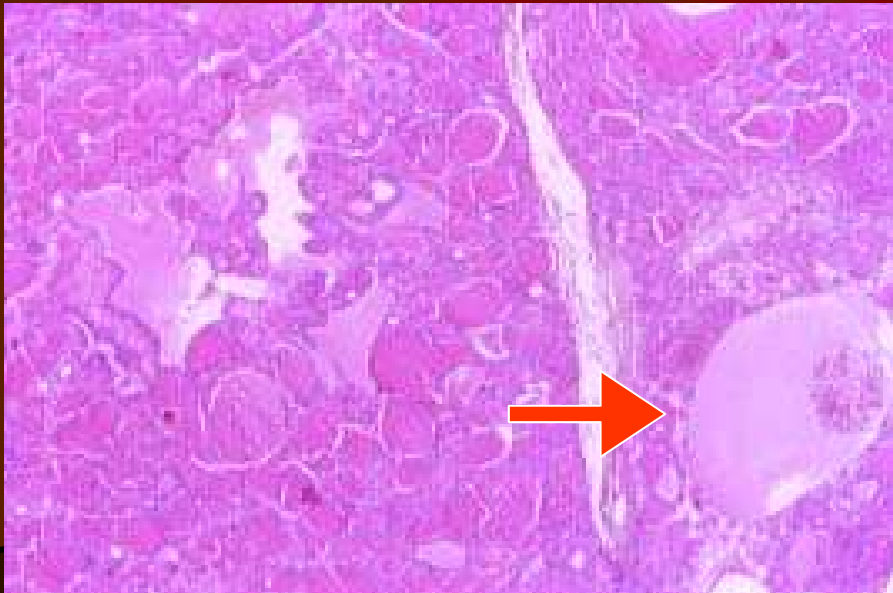


Prolifération lymphomateuse en nappes

***HES X 20***



Hyperlobulation débutante  
***HES X 2,5***



Lésion évoluée avec  
lacunes hématique et  
sidérophagie  
***HES X 2,5***

**Nous vous remercions  
pour votre présence et  
attention**